

Microscopic and histological study of *Sarcocystis* species infection in slaughter camel in Al-Diwaniyah Province, Iraq.

Duaa Mahammed Hassan  Noor Idan Jarad 

Department of Microbiology, College of Veterinary Medicine, University of Al-Qadisiyah, Al-Diwaniyah City, Iraq.

Submitted: September 24, 2024

Revised: December 11, 2024

Accepted: January 07, 2025

Abstract This study concerns the genus *Sarcocystis* representing a group of intracellular mainly tissue parasites of carnivores, but some species are considered responsible for sarcocystosis in humans. These parasites are known to affect domestic and wild animals and can result in meat contamination with considerable economic impact. This study was aimed at determining the prevalence of *Sarcocystis* in camels using microscopic methods and histopathological methods. This study was conducted in Al-Diwaniyah Province in Iraq. A total of 200 camels (male and female) of various age groups were sampled at a slaughterhouse in Al-Diwaniyah Province. Samples of esophagus and tongue tissues were taken from each animal, then subjected to histopathological analyses. Samples were stained histologically using the haematoxylin and eosin stain to determine microscopic structures. The results were examined using a light microscope. They revealed there were no macroscopic abnormalities in the *Sarcocystis*-infected camels. Histopathological examination of the esophagus and tongue samples revealed tissue lysis and the formation of cysts that clearly indicated a chronic infection. The widespread presence of *Sarcocystis* in camels in Al-Diwaniyah Province was confirmed, highlighting that any zoonotic potential of the parasite in this area cannot be ignored.

Keywords: Camels, *Sarcocystis*, Zoonotic

©Authors, 2025, College of Veterinary Medicine, University of Al-Qadisiyah. This is an open access article under the CC BY 4.0 license (<http://creativecommons.org/licenses/by/4.0/>).

Introduction The species currently classified in the genus *Sarcocystis* are exclusive intracellular tissue parasites. The sexual reproduction by which meiosis occurs and the polyploid ookinetes transform into sporocysts occurs in the enterocyte of carnivores. The carnivore host becomes infected by ingesting tissues of herbivores with encysted stage (1-5). Carnivores are primarily definitive hosts, while numerous herbivores and omnivores are interim hosts. Human intestines do not consistently make a suitable host for sexual reproduction, but three species are suspected to be *Sarcocystis* spp. with the ability to complete their life cycle with humans: *Sarcocystis hominis*, *Sarcocystis suihominis*, and *Sarcocystis hirsuta*. Sarcocystosis has been reported worldwide, and arbitrary symptoms are rare; however, epizootics and fatalities have been described in herbivorous and omnivorous animals (6-10).

Sarcocystis species and possible serotypes have been described as parasites of reptiles, birds, and mammals. *Sarcocystis* species are not life-threatening parasites of carnivores since the terminal host is generally unaware of the enteric irritation associated with the presence of the organism. The greatest such infection is of slaughtered animals with poorly developed sarcocysts; their meat is often condemned since these cysts can be large enough for detection by gross searching techniques. These parasites tend to be specific for hosts; however, their complete phenotypic plasticity has also resulted in their use as physical or molecular data sources (11-15). The infection in humans can be caused via consuming contaminated meat. It is known that the circulation of the heteroxenous forms of the parasite is geographically, ecologically, and epidemiologically specific, being associated with the risk of human infection (13). The presence of more than one type of

intermediate host and/or the presence of more than one definitive host species can favor the increase in the genetic variability of these protozoa. The parasitism of *Sarcocystis* spp. occurs, both in neurons and in the central nervous system myocytes (14).

Materials and methods

Ethical approval

The study was done according to the approval recorded under the number (1890) in 28/8/2023 issued by the College of Veterinary Medicine, University of Al-Qadisiyah, Iraq

Samples

The study included 200 camels (*Camelus dromedarius*) that were slaughtered in the abattoir of Al-Diwaniyah province, Iraq, between September 2022 and the end of April 2023. The camels ranged in age from less than 4 years to more than 4 years, with both male and female specimens included in the study.

Each camel provided 250 grams of tissues that were dissected from the esophagus, tongue, skeletal muscle and heart. Samples were divided into two portions: one part was fixed in 10 per cent neutral buffered formalin (NBF) for histopathology, and the other was transferred into plastic containers and was kept frozen. Specimens for histopathology were taken to the Department of Parasitology Department, College of Veterinary Medicine, University of Al-Qadisiyah, Al-Diwaniyah City, Iraq.

Histological Examination

Fixation: Tissue specimens were preserved in 10% formalin for 48 hours. **Dehydration:** The samples were sequentially immersed in ethanol solutions of 70 per cent, 80 per cent, 90 per cent and two times of 100 per cent ethanol, all for two hours. **Depolymerization:** The tissues were immersed in xylene for 30 min twice to ensure thorough depolymerization. **Infiltration and Embedding:** Tissues are embedded in paraffin (58°C) to allow the wax to solidify within the tissue matrix. Once solidified, samples are placed in the refrigerator for 24 h to allow the solidification of the paraffin. **Sectioning:** Tissue specimens embedded in paraffin were sectioned using a microtome with a width of 5-7 µm. The sections were dipped in a bath at 35-37°C and then mounted onto the slides. **Staining:** The tissue sections were visualized by the use of generalized tissue character staining with hematoxylin and eosin (H and E) and specific component of the tissue which was visualized by PAS staining. **Microscopy:** Sections were examined at x4,

This study was aimed at determining the prevalence of *Sarcocystis* in camels using microscopic methods and histopathological methods

x10, x20, x40 and x100 magnifications under an Olympus light microscopy.

Results

Macroscopic and microscopic examinations

Macroscopic examination showed that none of the 200 samples of meat obtained from slaughtered camels were positive, whereas the application of acid pepsin digestion coupled with further microscopic analysis revealed an obvious upward trend in the prevalence of *Sarcocystis* spp.

Histopathological findings

Esophagus

The histopathological images show sections of the esophagus obtained from infected camels with *Sarcocystis*, a parasitic organism. Two sections stained with Hematoxylin and Eosin (H&E) are shown to be infected with *Sarcocystis*. At lower magnification (X200), the muscularis layer appears to contain multiple elongated and oval cysts some parts have an opaque appearance disrupting the normal architecture and common orientation of the muscle fibers. At the higher magnification (X400), internal structure of these cyst are more prominent septations can be seen accompanied by bradyzoites which confirms the parasitic infection. The lining layer called epithelial layer is intact the lining of the muscle fiber layer appear to be fibrosis accessible and reactive changes are evident upon intense scrutiny likely due to chronic inflammation due to the parasite. This extensive parasitic involvement is suggestive of chronic infection. It is conceivable that the normal function of esophageal muscles is affected (Figure 1).

Tongue

The histopathological images demonstrate sections of the tongue from camels infected with *Sarcocystis* species as expressed by Hematoxylin and Eosin (H&E) dye. Image A at low magnification (X200) displays the muscularis layer (MM) of the tongue's underlining from the stratified squamous epithelium which appeared intact and presenting with prominent papillary projections. The muscularis layer is extensively infiltrated with *Sarcocystis* cysts notably disrupting the normal architecture of the muscle fibers. By Objective Field of View: Image B shows the muscularis layer of the camel tongue section at a high

magnification view (X400). It gave a more-in-depth detailed view of the abundant Sarcocystis cysts (S) in the muscle tissue. The cysts are well-defined with apparent internal septation and its contained parasitic worm that referred to bradyzoites. The plentiful Sarcocystis cysts indicate a fecund parasitic burden that possibly compromises the normal function of the tongue muscles in the camels affect their feeding and health status (Figure 2).

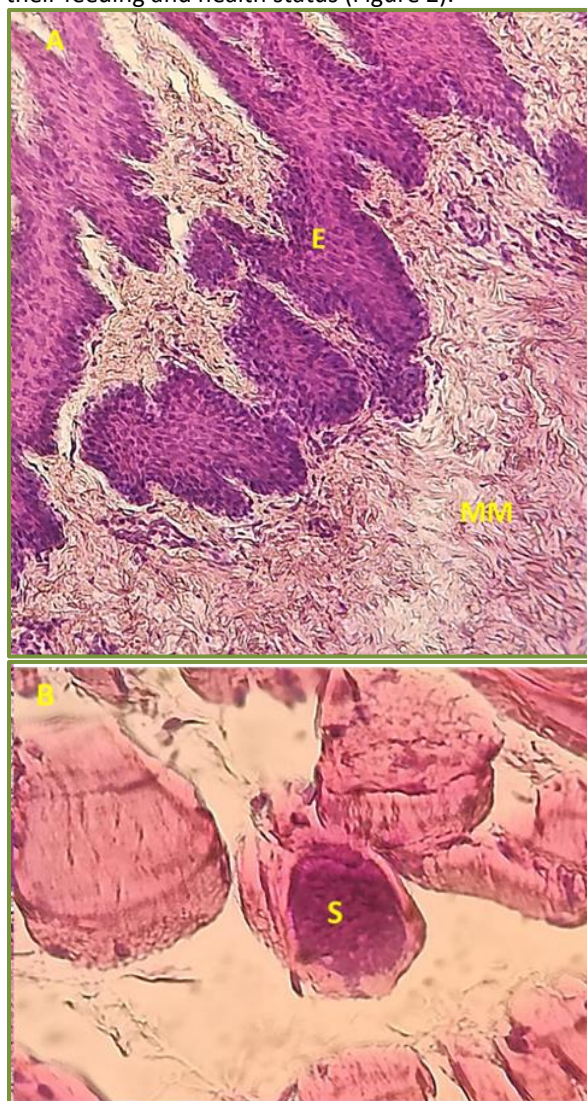


Figure 1: Histopathology of camel's esophagus stained with Hematoxylin and Eosin (H&E) (A) Low magnification (X200), the muscularis layer (MM) showing several oval-shaped Sarcocystis cysts interrupting normal muscle structure at low magnification (X200). Stratified squamous epithelium (E) on the overlying membrane appears normal. (B)

Superimposed Sarcocystis cysts at high magnification (X400): internal septations and bradyzoites (S) in the muscularis layer are clear (high parasitic load).

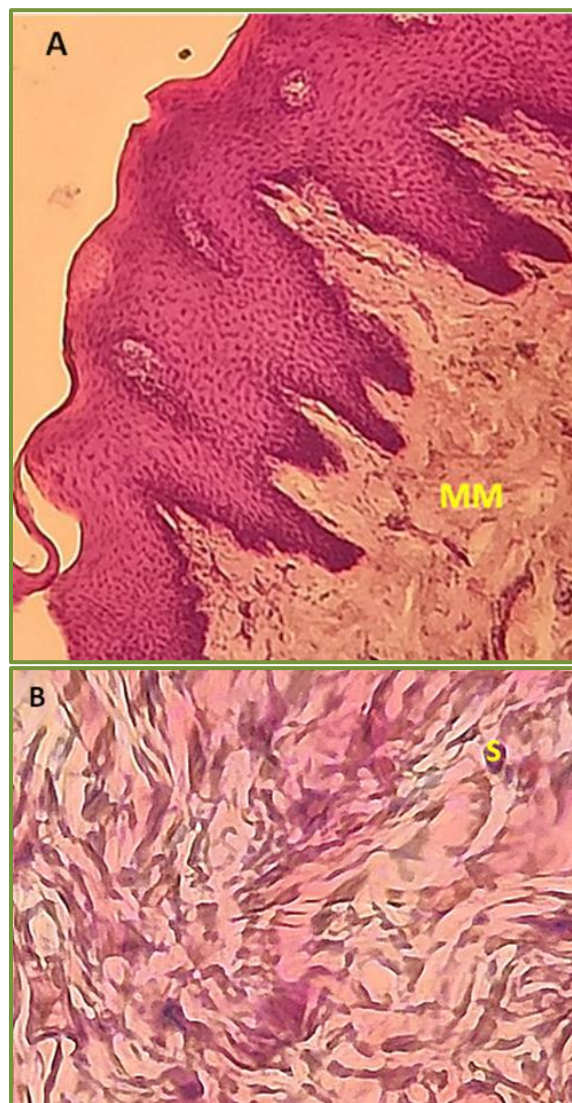

Figure 2: Histopathological Images of the Tongue in Camels Infected with Sarcocystis Stained with Hematoxylin and Eosin (H&E) Image A. Low Magnification (X200). The stratified squamous epithelium overlying the muscularis of tongue is intact with some papillary projections, Muscularis (MM): inner multilayered layer of tongue. Image B. High Magnification (X400). Sarcocystis cysts are clearly demarcated by septae and bradyzoites.

Discussion

In camels particularly, infection by *Sarcocystis* spp is mainly causing high economic and health burden. In

this study performed in Al Diwaniyah province, 70% of the camels were infected as detected by histological method (16). High percentage of parasitic burden within camels agrees well with previous reports from other regions but diagnostic techniques and geographical location could affect the prevalence (17). Furthermore, Metwally et al (18) recorded 17.8 % sarcocystis prevalence in camels from Upper Egypt. Camels in these regions show varying degrees of Sarcocystis infections, with studies reporting prevalences from 47 per cent up to 100 per cent The variability is further illustrated by research from Saudi Arabia (26), Egypt (18) and Iran (19). These studies, using similar methodologies based on both histology and molecular detection, reported a 65 per cent prevalence, a 75 per cent prevalence, and a 77 per cent prevalence, respectively. These numbers accentuate one of the benefits of modern molecular techniques over increased sensitivity.

Identifying Sarcocystis cysts in tissue samples also relies on histological methods (specifically, those that can be made out via microscope). However, histology might fail to detect ongoing infections, particularly when they're at early stages, and these methods also fail to differentiate between the various species of Sarcocystis. Histology is based on staining techniques. For example, histopathology generally involves the use of haematoxylin and eosin (H+E) and other stains to observe cysts under a microscope (20). However, histological methods aren't as sensitive as molecular techniques, meaning, among other things, that they fail to detect low-level infections that might not be visible to the naked eye. The molecular technique PCR and sequencing has been shown to be more sensitive for identifying infections. Recent molecular reports have increased our knowledge on animal species affected by Sarcocystis – and, as a result, also on the epidemiology of sarcocystosis – but molecular techniques have also sometimes yielded controversial results. For example, PCR has demonstrated the existence of a new Sarcocystis species called Sarcocystis suihominis, which is common in pigs but can infect humans. However, this species remains undetectable by diagnostic techniques (21).

Conclusion

Histopathological examination of the esophagus and tongue samples reveal tissue lysis and the formation of cysts that clearly indicated a chronic infection. The widespread presence of Sarcocystis in camels in Al-Diwaniyah Province was confirmed, highlighting that

any zoonotic potential of the parasite in this area cannot be ignored.

Acknowledgements

Not applicable.

Conflicts of Interest

The authors declare there is no conflict of interest.

Funding source

This research had no specific fund; however, it was self-funded by the authors.

References

1. Baranauskaitė A, Strazdaitė-Žielenė Ž, Servienė E, Butkauskas D, Prakas P. Molecular identification of protozoan Sarcocystis in different types of water bodies in Lithuania. *Life*. 2022;13(1):51. <https://doi.org/10.3390/life13010051>
2. Bezerra TL, Soares RM, Gondim LFP. Sarcocystis Species (Apicomplexa, Eucoccidiorida) Parasitizing Snakes. *Parasitologia*. 2023. <https://doi.org/10.3390/parasitologia3040032>
3. Castro-Forero SP, Bulla-Castañeda DM, Buitrago HL, Anaya AD, de Carvalho LM, Pulido-Medellín MO. Sarcocystis spp., a parasite with zoonotic potential. *Bulg J Vet Med*. 2022;25(2):175-86. <https://doi.org/10.15547/bjvm.2019-0129>
4. Chen Y, Peng J, Zhu Z, Zhang W, Wang L, Xu J, et al. Development of a highly specific LAMP assay for detection of Sarcocystis tenella and Sarcocystis gigantea in sheep. *Parasitol Res*. 2024;123(9):1-8. <https://doi.org/10.1007/s00436-024-08349-0>
5. Dubey JP, Rosenthal BM. Bovine sarcocystosis: Sarcocystis species, diagnosis, prevalence, economic and public health considerations, and association of Sarcocystis species with *Int J Parasitol*. 2023. <https://doi.org/10.1016/j.ijpara.2022.09.009>
6. Dubey JP, Sykes JE. Sarcocystosis. In: *Greene's Infectious Diseases of the Dog and Cat*. 2021. <https://doi.org/10.1016/B978-0-323-50934-3.00095-1>
11. Dubey JP, Fayer R, Rosenthal BM. Sarcocystis of animals and humans. CRC Press; 2015. <https://doi.org/10.1201/b19184>
12. Fayer R, Dubey JP. Protective immunity against clinical sarcocystosis in cattle. *Vet Parasitol*. 1984;15:187-201. [https://doi.org/10.1016/0304-4017\(84\)90071-2](https://doi.org/10.1016/0304-4017(84)90071-2)
7. Fayer R, Dubey JP. Sarcocystis spp. in human infections. *Clin Microbiol Rev*. 2004;17(4):894-902. <https://doi.org/10.1128/CMR.17.4.894-902.2004>
8. Fayer R, Esposito DH, Dubey JP. Human infections with Sarcocystis species. *Clin Microbiol Rev*. 2015;28(2):295-311. <https://doi.org/10.1128/CMR.00113-14>
9. Giorda F, Romani-Cremaschi U, Marsh AE, Grattarola C, Iulini B, Pautasso A, et al. Evidence for unknown sarcocystis-like infection in stranded striped dolphins (Stenella coeruleoalba) from the Ligurian sea, Italy. *Animals (Basel)*. 2021;11(5):1201. <https://doi.org/10.3390/ani11051201>

10. Gjerde B, Schulze J. Molecular characterization of *Sarcocystis* species in Norwegian cervids. *Parasitol Res.* 2014;113(12):4133-46.
<https://doi.org/10.1007/s00436-014-3806-z>
11. Greenfield JB, Anderson MV, Dorey EA, Redman E, Gilleard JS, Nemeth NM, et al. Molecular characterization of *Sarcocystis* spp. as a cause of protozoal encephalitis in a free-ranging black bear. *J Vet Diagn Invest.* 2022;34(1):146-52.
<https://doi.org/10.1177/10406387211038389>
12. Hilali M, Fatani A, Al-Atiya S. Isolation of tissue cysts of *Toxoplasma*, *Isospora*, *Hammondia*, and *Sarcocystis* from camel (*Camelus dromedarius*) meat in Saudi Arabia. *Vet Parasitol.* 1995;58:353-6.
[https://doi.org/10.1016/0304-4017\(94\)00727-T](https://doi.org/10.1016/0304-4017(94)00727-T)
13. Hussein HS, Warrag M. Prevalence of *Sarcocystis* in food animals in the Sudan. *Trop Anim Health Prod.* 1985;17:100-1.
<https://doi.org/10.1007/BF02360781>
14. Ishag MY. Studies on *Toxoplasma* and *Sarcocystis* from camels (*Camelus dromedarius*) in the Sudan. [Thesis]. University of Khartoum; 2003.
15. Islam KU, Iqbal J. An update on molecular diagnostics for COVID-19. *Front Cell Infect Microbiol.* 2020.
<https://doi.org/10.3389/fcimb.2020.560616>
16. Kirmse P, Mohanbabu B. *Sarcocystis* sp. in the one-humped camel (*Camelus dromedarius*) from Afghanistan. *Br Vet J.* 1986;142:73-4.
[https://doi.org/10.1016/0007-1935\(86\)90012-6](https://doi.org/10.1016/0007-1935(86)90012-6)
17. Aggar OA, Al-Zubaidi MTS. Molecular identification and phylogenetic confirmation of *Sarcocystis* species in slaughtered camels in Al-Najif Province, Iraq. *Open Vet J.* 2023.
<https://doi.org/10.5455/OVJ.2023.v13.i9.5>
18. Metwally DM, Al-Otaibi TT, Al-Turaiki IM, El-Khadragy MF, Alajmi RA. Identification of *Sarcocystis* spp. in one-humped camels (*Camelus dromedarius*) from Riyadh and Dammam, Saudi Arabia, via histological and phylogenetic approaches. *Animals (Basel).* 2020;10(7):1108.
<https://doi.org/10.3390/ani10071108>
19. Mohamed RH, Elmahallawy EK. Epidemiological and histopathological investigation of *Sarcocystis* spp. in slaughtered dromedary camels (*Camelus dromedarius*) in Egypt. *Vet Sci.* 2020;7(4):162.
<https://doi.org/10.3390/vetsci7040162>
20. Hamidinejat H, Hekmatimoghaddam S, Jafari H, Sazmand A, Haddad Molayan P, Derakhshan L, et al. Prevalence and distribution patterns of *Sarcocystis* in camels (*Camelus dromedarius*) in Yazd Province, Iran. *J Parasit Dis.* 2013;37:163-5.
<https://doi.org/10.1007/s12639-012-0150-z>
21. Eslampanah M, Motamedi GR, Dalimi A, Noori A, Habibi GR, Aghaeepour K, Niroumand M. Study of camel and goat *Sarcocystis* by electron microscopic and PCR-RFLP. *Vet Res Biol Prod.* 2016;29:77-84.
<https://doi.org/10.22034/vj.2016.106301>