


Investigation of the relationship between Myoz1 gene expression, glycogen levels, and age in the iliofibularis muscle of broiler chickens (*Gallus gallus domesticus*)

Ahmed Abdulshahid Baqer Nabeel Abd Murad Al-Mamoori 

Department of Anatomy and Histology, College of Veterinary Medicine, University of Al-Qadisiyah, Al-Diwaniyah

Submitted: June 07, 2024

Revised: July 25, 2024

Accepted: July 29, 2024

Abstract This study aimed to investigate the histological growth and Myoz1 gene expression and evaluated the level of glycogen in the iliofibularis muscle of broiler chickens at 2, 4, and 5 weeks of age. By investigating the structural changes in muscle fibers and the corresponding alterations in Myoz1 gene levels, this research sought to elucidate the relationship between age, muscle growth, and gene expression in the iliofibularis muscle group. Understanding these developmental processes is crucial for optimizing broiler production and potentially providing insights into muscle growth and development in other species. In this study, fifteen broiler chickens were examined to investigate the histological structure and evaluate the level of the Myoz1 gene in the iliofibularis muscles at three different ages: 2 weeks, 4 weeks, and 5 weeks. The muscle fibers are cylindrical and multinucleated, with elongated nuclei beneath the sarcolemma. The muscle fibers are surrounded by a very thin layer of endomysium, which is composed of fibroelastic connective tissue. Each fascicle of muscle fibers is surrounded by a dense, irregular connective tissue called the perimysium. A cluster of muscle fascicles is surrounded by a layer of dense, irregular connective tissue called the epimysium. The size and organization of muscle fibers increase with age. At 5 weeks, the muscle fibers become larger and more uniform. The mean areas of muscle fibers at 2 weeks, 4 weeks, and 5 weeks were 233.1 ± 0.0099 , 492.32 ± 0.0079 , and 1177.56 ± 0.0098 μm^2 , respectively. Our results show the muscle fibers in the third group had a highly significant difference from the muscle fibers of the iliofibularis muscle in the first and second groups. The highest average expression was found in the third group (5 weeks old), while the lowest was in the first group (2 weeks old). Our findings indicate statistical analysis confirmed iliofibularis muscle in the third group had a highly significant difference with iliofibularis muscle in the first and second groups ($P=0.0000269$) and ($P=0.000025$), respectively. Overall, the findings suggested an age-dependent rise in myoz1 gene expression within the iliofibularis muscle in the third group of broiler chickens.

Keywords: Broiler chicken, gene expression, glycogen, Myoz1 gene, iliofibularis muscle

©Authors, 2025, College of Veterinary Medicine, University of Al-Qadisiyah. This is an open access article under the CC BY 4.0 license (<http://creativecommons.org/licenses/by/4.0/>).

Introduction Poultry meat is an essential source of high-quality proteins, vitamins, and minerals for a balanced human diet and is also regarded as lower in fat, making it a better choice for people who need to reduce their fat (1, 2, & 3). In ducks, the average skeletal muscle was 73% and 2.3% adipose tissue, and they have a high level of protein and a lower fat content than other animals (4). In broiler chickens, the skeletal muscle characteristics are morphological, suitable for meat production, and form nearly half of the body weight. The quantity of muscle fibers and muscle hypertrophy that regulate muscle mass and embryonic myogenesis is referred to as the mechanism for muscle building (5). Broiler chickens

have the ability to rapidly grow and convert feed into skeletal muscles, making them an important source of animal protein globally (6). There is a positive relationship between the quality of broiler meat, nutritional content, and the level of expression of the Myoz1 gene. In chickens, the size and faster-twitching of muscle fibers are associated with increased levels of the Myoz1 gene, and this is associated with increased juiciness and tenderness (7). Skeletal muscles with increased Myoz1 levels are perceived to have better tenderness, texture, and yield, which may positively impact consumer perceptions of nutritional value (8, 9). Presently, very few studies have estimated the expression of Myoz1 and glycogen in

the skeletal muscle of broiler chickens. So, this study aimed to investigate the histological growth and Myoz1 gene expression and evaluated the level of glycogen in the iliofibularis muscle of broiler chickens at 2, 4, and 5 weeks of age. By investigating the

Material and Methods

Ethical Approval

The investigation was ethically certified by the College of Veterinary Medicine ethics committee at University of Al-Qadisiyah, Iraq, resulting in the issuance of an ethical approval number, 1890 in 28/8/2023.

Collection of specimens

In the present study, fifteen broiler chickens were collected from a poultry farm in Al-Diwaniya city from November to December 2023. Broiler chicken was divided into three groups according to age at 2, 4, and 5 weeks old. The chickens were anesthetized by inhalation of chloroform for three minutes in a closed box. After that, the chickens were slaughtered and left to ensure complete bleeding. Dissect the chickens and remove the skin to expose the iliofibularis muscle in the thigh region. The specimens were collected from each group and divided into two groups: histochemical study, in which the specimens were preserved in 10% neutral buffered formalin (NBF), and gene expression, in which the specimens were preserved in AccuZol™ total RNA extraction reagent (Bioneer, South Korea) for real-time quantitative polymerase chain reaction (RT-qPCR) in 80 C.

Histochemical process of tissue

For the histological study, fix the specimens in 10% NBF for 48 hours at room temperature; after that, wash the specimens with tap water for two hours, and then dehydrate the specimens by ascending series of alcohol, starting with 50% and ending with 100%. The next step is clearing by xylene two times for five minutes; infiltration of the specimens by paraffin wax two times for two hours. Right after that, block with paraffin wax. After the wax hardens, section to 6 µm. And after that, mounting on a glass slide; and lastly, staining with Mayer's hematoxylin and eosin to detect the general histological structure of muscle fibers and periodic acid Schiff (PAS) to detect the glycogen in muscle fiber tissue. The tissue sections were then mounted with DPX media and left for 24 hours to adhere (10). After imaging histological sections, the measurements were recorded using ImageJ software.

Gene expression study

Fifteen healthy, fresh muscle specimens for gene expression were collected from the same area where

structural changes in muscle fibers and the corresponding alterations in Myoz1 gene levels, this research sought to elucidate the relationship between age, muscle growth, and gene expression in the iliofibularis muscle group.

the samples for histochemical examination were taken from three groups, each weighing approximately 100 mg. The specimens were placed directly into Eppendorf containers containing sufficient TRIzol® Total RNA Extraction Solution. The specimens were stored in a refrigerator until all the samples were collected and tested. Real-time PCR was used to quantify the myoz1 gene normalized to the housekeeping gene (GAPDH) in the iliofibularis muscle tissue of broiler chickens. The method was performed as described (11) and included the following steps:

Screening of genes

Table 1: Explain primers used in current study with their references

Gene (bp)		Sequence (5'-3')	Amplicon
Myoz 1 (76)	F	AGAAAGCAGCCAAAC GGATG	XM_42161 9.7
	R	AACACGAGCGATTCTG GAAG	
GAPD H (86)	F	TGGCATTGCACTGAAT GACC	NM_20430 5.2
	R	TCAAGTCCACAACACG GTTG	

Total RNA Extraction and Estimation

The extracted total RNA from iliofibularis muscle specimens using the TRIzol® reagent kit (Bioneer, Korea) following the manufacturer's instructions. The extracted RNA was measured using a Nanodrop spectrophotometer and stored at -20°C. To assess RNA quality and measured its concentration (ng/µL) and purity by determining the absorbance ratio at 260 nm to 280 nm.

DNase I Treatment and cDNA Synthesis to remove trace amounts of genomic DNA contamination from the extracted RNA, The Total RNA was treated with DNase I enzyme (Promega, USA) and the cDNA synthesis was done using M-MLV Reverse Transcriptase kit according to the manufacturer's protocol.

qPCR Master Mix Preparation and Thermal Cycling Conditions

The qPCR master mix was prepared using the GoTaq® qPCR Master Mix kit (Promega, USA) with SYBR Green dye for real-time PCR amplification of the target gene

myoZ1 and the housekeeping gene GAPDH. The followed the protocol provided by the manufacturer

Data Analysis of RT-qPCR

The relative gene expression levels (fold change) were calculated using the ΔCT method with GAPDH as the reference gene. The equation used for this analysis was:

$$\text{Gene expression ratio} = 2^{-(CT(\text{Housekeeping gene}) - CT(\text{Target gene}))}$$

Statistical analysis

The histometric of muscle tissue and RT-qPCR raw data were analyzed using SSPS computer program 2019 (Microsoft, USA). The means and standard errors of the area of muscle fiber and gene for three groups were determined, and the Myoz 1 expression in different ages was assessed using univariate analysis of variance with a least significant difference (LSD) of P0.05 to compare within groups and between groups.

Results

In the current study, the three groups of broiler chickens, depending on age (two weeks, four weeks, and five weeks), were used to describe the histochemical structure and level of the Myoz1 gene in iliofibularis muscle. Grossly, the iliofibularis muscle is located in the cranio-lateral aspect of the thigh region of the chicken. The muscle extends from the ilium to the fibula, seemed white in color. Histologically, the iliofibularis muscle consists of cylindrical, multinucleated muscle fibers with elongated nuclei located under the sarcolemma (Figure 1).

The single muscle fibers within the muscle bundles were encircled by endomysium, and it was a thin and delicate layer and consisted of connective tissue fibers. It covered the outer layer of individual muscle fibers and surrounded nerve fibers and capillaries. Myofibril striations can be seen in the longitudinal section of the muscle fiber; in addition, myofibril bundles can also be seen in the cross section. Muscle fibers are arranged into bundles, held together by dense, irregular connective tissue between bundles. This connective tissue forms the perimysium around each muscle fiber bundle. Connective tissue is filled

with small blood vessels. A group of muscle bundles is surrounded by a layer of dense, irregular connective tissue called the epimysium, which forms the muscle mass of the iliofibularis muscle. There is a difference in the organization, shape, and size of muscle fibers between the three groups. In the first group at two weeks' old, there was a decrease in the size and organization of the fibers, with a few large and medium fibers spreading between the small fibers. We notice that muscle fibers are more organized, and their size is somewhat similar with the increasing age of broiler chickens. However, in the third group after 5 weeks, the size and organization of the fibers have increased, and the majority of them appear to be of the same size and distributed in a uniform manner (Figure 1). The mean areas of muscle fibers at 2 weeks, 4 weeks, and 5 weeks were 233.1 ± 0.0099 , 492.32 ± 0.0079 , and $1177.56 \pm 0.0098 \mu m^2$, respectively. Our findings showed a positive reaction for PAS in different degrees according to the amount of glycogen found in the muscle fibers of the iliofibularis muscle. The glycogen content appeared in purple granules, mainly located between the myofibrils (Figure 2).

In the current study, evaluated Myzo1 gene expression in the iliofibularis muscle of broiler chickens across different age groups. The gene expression analysis revealed an increase in the average gene expression with age. The highest average expression was found in the third group (5 weeks old), while the lowest was in the first group (2 weeks old), as shown in Table 1. Our findings indicate that statistical analysis confirmed iliofibularis muscle in the third group displayed a highly significant difference with iliofibularis muscle in the first and second groups ($P=0.0000269$) and ($P=0.000025$), respectively, whereas there was no significant difference between the first and second groups of iliofibularis ($P=0.986296$) (Figures 3, 4 & 5).

Table 2: Myzo1 gene expression in the iliofibularis muscles in three groups (2, 4 and 5 weeks old) of broiler chickens (mean \pm SE; n=5 each group)

First group (2 Weeks)	Second group (4 Weeks)	Third group (5 Weeks)
11.79 \pm 1.93	11.74 \pm 1.99	25.69 \pm 2.01

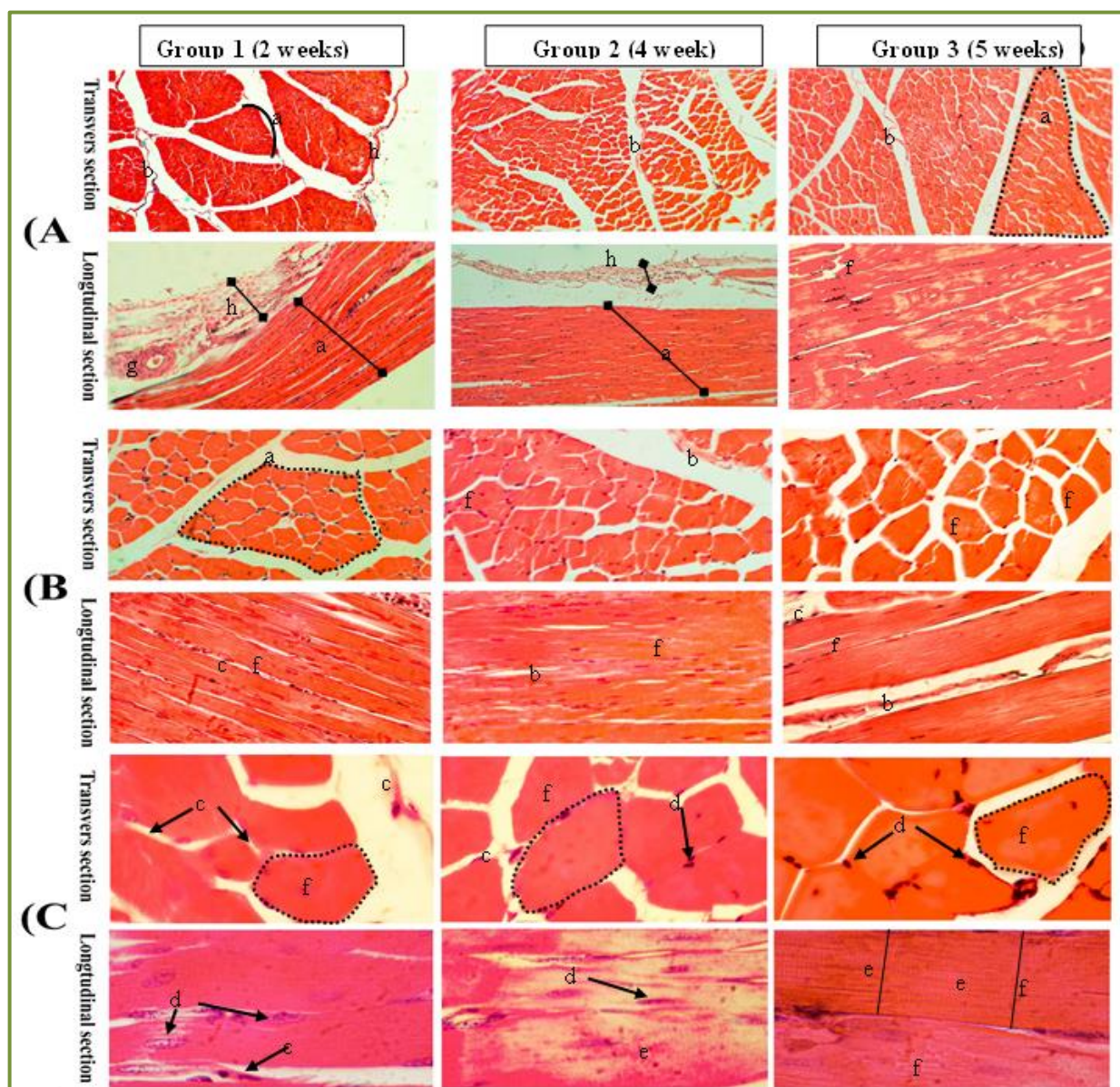


Figure 1: Images illustrate the histological structure of the iliofibularis muscle tissue of broiler chicken for different groups. Indicator: a- Bundle of muscle fibers (fascicles) b- Perimysium c- Endomysium d- Nucleus e- Striation of muscle fiber f- Muscle fiber g- Blood vessels) H&E stain A- 100X, B- 400X and C- 1000X.

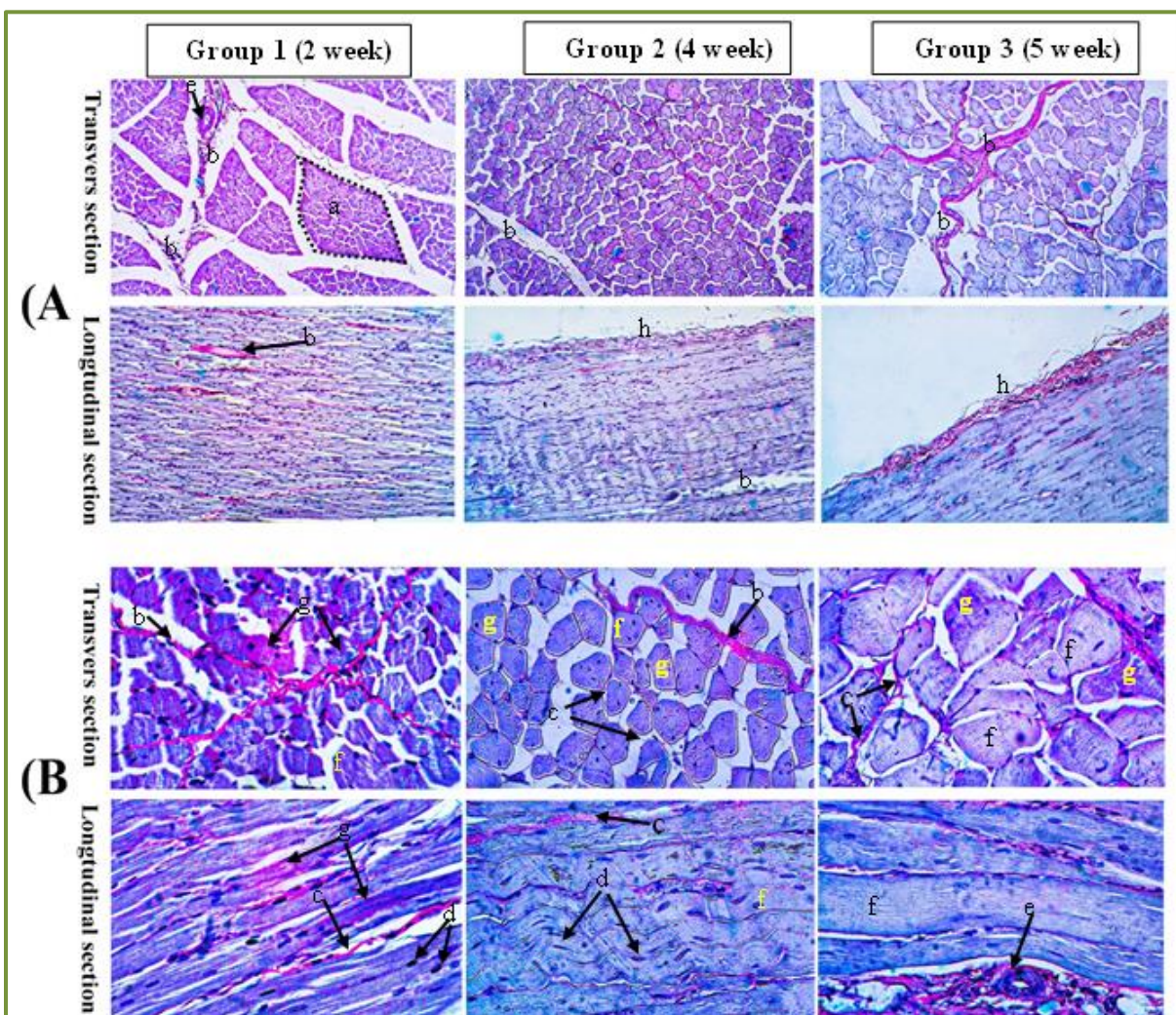


Figure 2: Images illustrate the histological structure of the iliofibularis muscle tissue of broiler chicken for different groups. Indicator: a- Bundle of muscle fibers (fascicles) b- Perimysium c- Endomysium d- Nucleus e- Blood vessels f- Muscle fiber g- Glycogen. H&E stain A- 100X, B- 400X and C- 1000X, PAS stain A- 100X, B- 400X.

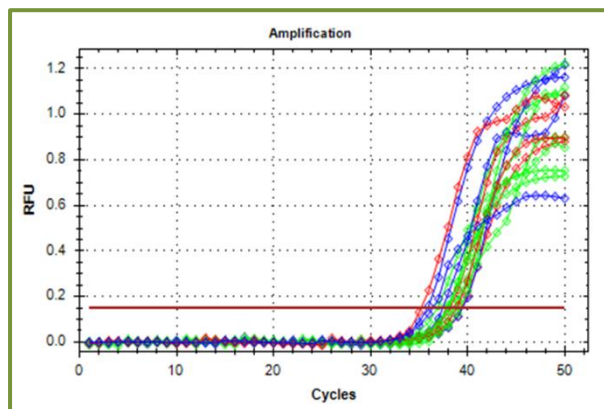


Figure 3: Real Time PCR amplification plots of myoz1 gene in iliofibularis muscle tissue of experimental broiler chicken. The green plots (2weeks), the blue plots (4 weeks), and the red plots (5weeks).

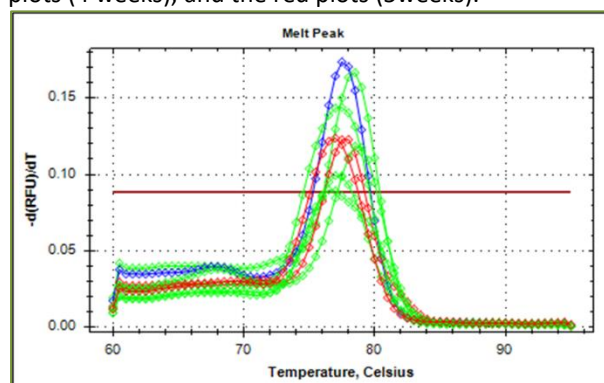


Figure 4: Real-Time PCR melting peaks of myoz1 gene in iliofibularis muscle tissue of experimental broiler chicken. that showed melting peak at Tm:78C.

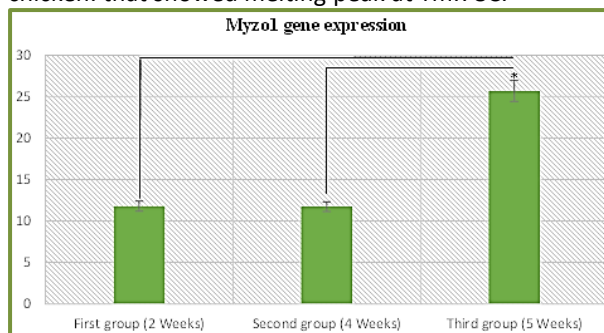


Figure 5: Total expression of the Myzo1 gene expressed in iliofibularis muscles of broiler chickens at a different stage of age. Each column represents the group and age of the broiler chickens. Three groups (p = 0.05) displayed significantly higher values between groups. * Indicates significant values derived using univariate analysis of variance.

Discussion

In this study, fifteen broiler chickens were examined to investigate the histological structure of the iliofibularis muscle fibers in three groups. Where observed the muscle fibers has the same histological structure cylindrical, multinucleated, and had elongated nuclei located peripherally. This result agrees with (12, 13, &14). However, we observed differences in the shape and size of muscle fiber between groups of our study. This finding agrees with (15, 16 & 17), which find the myofibers' diameters vary according to age. Our finding for the third group is that the fibers have grown in size and have become more organized and the same size. The mean muscle fiber area increased significantly from 2 weeks to 5 weeks, reflecting muscle growth of 233.1 ± 0.0099 , 492.32 ± 0.0079 , and $1177.56 \pm 0.0098 \mu m^2$, respectively. Also, we noticed varying degrees of glycogen content taking on a purple color in the muscle fibers; these are in line with the previous finding that the glycogen in avian skeletal muscles is not evenly distributed (18).

The expression of the Myoz1 gene increased with age, and it was highest in the third group, whereas the second group had the lowest. There was a direct positive association between the Myoz1 level and the nutritional value and quality of broiler chicken meat. The Myoz1 gene is a regulatory protein involved in muscle contraction. Researchers have also connected the larger and faster-twitch muscle fibers in chickens to higher expression of the Myoz1 gene, and larger muscle fibers in chicken flesh are associated with higher levels of tenderness and juiciness. Consequently, it is believed that meat with increased Myoz1 levels will have superior texture, tenderness, and yield (6, 16). The growth and development of meat duck muscles are significantly regulated by the Myoz1 gene (7).

Conclusion

Our research shows a strong correlation between the Myoz1 gene expression and the aging-related increase in the number and structure of muscle fibers. This demonstrates a strong correlation between the gene and the cellular level to support the growth and development of muscles in broiler chickens. Higher expression of the Myoz1 gene can lead to improved protein synthesis and the ability to produce powerful muscular contractions, both of which are beneficial for muscle development because the Myoz1 gene regulates a regulatory protein involved in muscle contraction. This outcome is consistent with (19).

Conflict of interest

Authors declare no conflict of interest.

Funding source

This research had no specific fund; however, it was self-funded by the authors.

References

1. Bessei W. Welfare of broilers: a review. *World's Poultry Sci J.* 2006;62(3):455-466. <https://doi.org/10.1079/WPS2005108>
2. Alagawany M, Elnesr SS, Farag MR, Tiwari R, Yatoo MI, Karthik K, Michalak I, Dhama K. Nutritional significance of amino acids, vitamins and minerals as nutraceuticals in poultry production and health: A comprehensive review. *Vet Q.* 2020;41(1):1-29. <https://doi.org/10.1080/01652176.2020.1857887>
3. Kanakachari M, Bhattacharya TK. Transcriptome analysis reveals potential mechanisms and pathways underlying embryonic development with respect to muscle growth and egg production in slow and fast-growing chickens. *Animals.* 2022;12(18). <https://doi.org/10.3390/ani12182394>
4. Bombik E, Pietrzakiewicz K, Bombik A. Analysis of the fatty acid profile of the tissues of hunted mallard ducks (*Anas platyrhynchos* L.) from Poland. *Animals.* 2022;12(18). <https://doi.org/10.3390/ani12182394>
5. Aw-Hassan A, Shomo F, Iniguez L. Trends in small ruminant meat production-consumption gaps in West Asia and North Africa: Implications for intra-regional trade. *Outlook Agric.* 2010;39(1). <https://doi.org/10.5367/000000010791170031>
6. Fatchiyah F, Rohmah RN, Triprisila LF, Virginia RP, Rahayudi B, Kurnianingsih N, Safitri A, Abdul Razis AF. The expression of Myoz1 and ApoB is positively correlated with meat quality of broiler chicken. *Vet Med Int.* 2022. <https://doi.org/10.1155/2022/3266076>
7. Zhou T, Wu Y, Bi Y, Bai H, Jiang Y, Chen G, Chang G, Wang Z. MYOZ1 gene promotes muscle growth and development in meat ducks. *Genes.* 2022;13(9). <https://doi.org/10.3390/genes13091574>
8. Suman SP, Joseph P. Myoglobin chemistry and meat color. *Annu Rev Food Sci Technol.* 2013;4(1):79-99. <https://doi.org/10.1146/annurev-food-030212-182623>
9. Henchion M, McCarthy M, Resconi VC, Troy D. Meat consumption: Trends and quality matters. *Meat Sci.* 2014;98(3):561-568. <https://doi.org/10.1016/j.meatsci.2014.06.007>
10. Suvarna SK, Layton C, Bancroft JD. Bancroft's theory and practice of histological techniques. Nottingham, UK: Elsevier; 2013.
11. Kong BW, Hudson N, Seo D, Lee S, Khatri B, Lassiter K, Cook D, Piekarski A, Dridi S, Anthony N, Bottje W. RNA sequencing for global gene expression associated with muscle growth in a single male modern broiler line compared to a foundational Barred Plymouth Rock chicken line. *BMC Genomics.* 2017;18(1). <https://doi.org/10.1186/s12864-016-3471-y>
12. Atabo D. Gross and histological studies of muscles of flight in some avian species. *Arch Anim Poultry Sci.* 2020;1(4). <https://doi.org/10.19080/AAPS.2020.01.555566>
13. Endo H, Tsunekaw N, Kudo K, Oshida T, Motokawa M, Sonoe M, Wanghongsa S, Tirawattanawanich C, Phimpachanhvongsod V, Takeshi S, Takahiro Y, Akishinonomiya F. Comparative morphological study of skeletal muscle weight among the red jungle fowl (*Gallus gallus*) and various fowl breeds (*Gallus domesticus*). *J Exp Zool B Mol Dev Evol.* 2021;338:542-555. <https://doi.org/10.1002/jez.b.23111>
14. Achouri A, Melizi M, Belbedj H, Azizi A. Comparative study of histological and histo-chemical image processing in muscle fiber section of broiler chicken. *J Appl Poultry Res.* 2021;30(3). <https://doi.org/10.1016/j.japr.2021.100173>
15. Telley IA, Denoth J, Stüssi E, Pfitzer G, Stehle R. Half-sarcomere dynamics in myofibrils during activation and relaxation studied by tracking fluorescent markers. *Biophys J.* 2006;90(2):514-530. <https://doi.org/10.1529/biophysj.105.070334>
16. Livak KJ, Schmittgen TD. Analysis of relative gene expression data using real-time quantitative PCR and the 2^{-C_T} method. *Methods.* 2001;2(5):402-408. <https://doi.org/10.1006/meth.2001.1262>
17. Mazzone M, Petracci M, Meluzzi A, Cavani C, Clavanzani P, Sirri F. Relationship between pectoralis major histology and quality traits of chicken meat. *Poult Sci.* 2015;94(1):123-130. <https://doi.org/10.3382/ps/peu043>
18. Mellor DB. The influence of glycogen on meat tenderness. *Texas Agric Exp Station, College Station, Texas.* 1985;1:1028-1034. <https://doi.org/10.3382/ps.0371028>
19. Ren RM, Liu H, Zhao SH, Cao JH. Targeting of miR-432 to Myozenin1 to regulate myoblast proliferation and differentiation. *Genet Mol Res.* 2016;15. <https://doi.org/10.4238/gmr15049313>