



Histopathological study of the effect of treatment with *Nigella sativa* against Iron stress in liver

Zahraa Mohammed Habeeb Salim Hussein jari

Department of physiology College of Veterinary Medicine University of Al-Qadisiyah, Iraq .

Corresponding Author Email : vet.post33@qu.edu.iq

- This article is a part of the master thesis of the first author.

Abstract

This experiment was conducted for the purpose of knowing the impact of antioxidant nanoparticles of *Nigella sativa* agonist oxidative stress of the Nanoparticles the iron in rats .the experiment was done in veterinary medicine Al-Qadisiyah university at the animal house .This study was carried out during a period from 20.11.2020 to 20.04.2021 (64) sixty four mature rat 90 days age , average body weight (100-120) gram were used in the current study the rat were kept under controlled hygienic condition with free access to food and water for two week before starting the experiment. The animal were randomly assigned into 4equal groups 16 each and treated as follow. Experimental design :-first group(control) :will be kept without treatment as negative control .Second group (IONP) :Will be orally administered with IONPs (10 mg\kg\day) for 28 days .Third group (NSMNP) : Will be orally administered with NSMNPs(25 mg \ Kg) for 28 day .Forth group (IO+NSMNP) mix : will be orally administered with combination of IONPs(10mg\kg\day) and NSMNPs (25mg\ kg \day)for 28day.Each group will be allocated to two subgroup as follow: Subgroup 1:8 male rats will be sacrificed after 14 days of treatment .Subgroup 2:8 male rats will be sacrificed after 28 days of treatment. The following objective will be studied ,and the most important changes observed Histological examination when administration after 14 and 28 days administration Nanoparticles showed on liver slid Iron loss hepatic cords necrosis hepatocytes and around central vein, congestion blood vessel inflammatory cells macrophages ,hyperplasia in bile duct ,congestion bile duct ,marked of dilation of sinusoids, hemorrhage within the hepatic tissue ,proliferation of kupffer cells ,binucleated hepatocytes compared with control. mix groups(IO+NSMNP) showed marked mitotic division of hepatocytes which showed as binucleated ,Congestion and dilation of sinusoids with proliferation of Kupffer cells ,showed of radially arrangement of hepatocytes around of central vein, appearance (hexagonal shape with prominent ¢ral nuclei) and few showed as binucleated hepatocytes .Dilation of sinusoids and present of Kupffer cells . with scattered and mild infiltration of macrophages and few congestion in the blood vessels .The hepatocytes showed with normal shape, compared with control. When administration Nanoparticles *Nigella sativa* normal Gross section obtained from liver tissue normal radially arrangement of hepatic cords around normal central vein. Binucleated hepatic cords around normal central vein. Binucleated hepatocytes, compared with control.

Keywords: *Nigella sativa*, nanoparticles, Iron stress

Introduction

The term Nanotechnology has been extremely developed field all over the world , producing various nanomaterial with alteration in many different physicochemical and physical properties including crystalline nature, size ,shape, as well as interaction with

many biological systems (1) (2) (3). Black grain of found 14 species, belongs to a family Ranunculaceae , to *Nigella sativa* found in Europe Asia, and Africa. The morphology tall Black seed to 20 - 90 cm ,with end divided leaves ,the leaf straight narrowly



linear to threadlike. the pale blue or pale purple , yellow , pink white, whit 5 - 1 0 petals flowers (4). The Black grain constituents a amount of volatile oils and vitamins. (5) s ,protein ,and alkaloid saponins (6)(7)(8). the oil and the seeds contain , basic unit thymoquinone , have shown medicinal properties in old medicine (9). It has been shown that both aqueous extract and alcoholic extract of the seed were working against of different organism even those were resistance of antibiotic (10)(11). Modern trials have proved that its seeds alone or in combination with other drugs are highly effective in diabetes mellitus (12)(13) and improves lipid profile through increasing HDL and decreasing LDL and triglycerides (8)(13). **The Aim of study**

The present study aims to investigate the antioxidant role of black seed nanoparticle NSMNPs on induced oxidative stressed IONPs male rate .

Material and Method Experimental design :-

1-frist group(control) :will be kept without treatment as negative control.

2-Second group (IONP) :Will be orally administered with IONPs (10 mg\kg\day) for 28 days (14).

3-Third group (NSMNP) : Will be orally administered with NSMNPs(25 mg \ Kg) for 28 day .

4-Forth group (IO+NSMNP): will be orally administered with combination of IONPs(10mg\kg\day) and NSMNPs (25mg\ kg \day)for 28day.

Preparation of Black Seeds Extract .

Methanolic extract has been obtained according to(15) using Sox let apparatus as

follow Preparation alcoholic extract *Nigella sativa* seeds will be purchase from the local market. Alcoholic extract will be prepared by as described by seeds will be washed with distal water several times ,dried at 50 c and crushed in a matter with pestle. 150 ml distal water 70%concentration ethanol 350 ml ,the with 45 gram *Nigella sativa* and preparation sox let apparatus. in 2021\3\9 time 9:00 am to 02:00pm

Biosynthesis of magnetic nanoparticles of *Nigella sativa* seed alcoholic extract .

Some of the *Nigella sativa* alcoholic xtract will be added drop wise with 50ml -0.1 M Fe cl₃.6H₂O.solution in 1:1..ration at room temperature , 1M NaoH Will be added till the PH become 11the confirmation alkaloids solution result mixed will be stirred using magnetic stirrer for 30 mint and former of intense black color solution will be confirmed synthesis Iron oxide nanoparticles the NPs will be used a apparatus separated by centrifugation 800 rpm for 20 mint and cleansed by washing ethanol alcoholic 3 mint after that wash water 3mint.the NPs will be end pour on dishes dried in hit oven 80 c for 3h and will be stored in seal light container further usr(17).

Each group will be divided into two subgroup as follow for taken sample :

A-Subgroup 1:8 male rats will be sacrificed after 14 days of treatment .

B-Subgroup 2:8 male rats will be sacrificed after 28 days of treatment.

Histological study:

**Preparation of histological sections: (18).
Staining of histological sections (H & E).**

Results.

Control group (14,28) days will be kept without treatment as negative control.

Control group Figure (1) in (14,28) days There is no change in normal tissue ,normal hepatic cords around central vein H&EX200.

2- After 14 days Iron groups treatment administration to male rate .

Figure (2)Gross section obtained from Liver tissue in male rats 14days shows there is loss to hepatic architecture and mild hyperplasia and congestion of bile duct, marked dilation of sinusoids, the necrosis of hepatocyte with dilation of sinusoid , hemorrhage with in the hepatic tissue , proliferation of kupffer cells and some hepatocytes



showed binucleated ,shows Infiltration of inflammatory cells, degeneration and loss of sinusoid, shows higher magnification, there is infiltration of macrophages and lymphocytes .necrosis of proliferation of kupffer cells and dilation of sinusoids H&EX200.

2.1. After 28 days Iron groups treatment administration to male rate .

Figure (3)Gross section obtained from liver tissue in male rats28 days showed loss of hepatic cords of hepatocytes around the central vein, dilation of sinusoids with infiltration of inflammatory cells and marked hyperplasia of bile duct , showed higher magnification, there is infiltration of inflammatory cells mainly macrophages. Necrosis of hepatocytes and few numbers of hepatocytes showed binucleated cells, showed hemorrhage and infiltration of macrophage, Necrosis of hepatocytes, showed marked hyperplasia of bile duct , loss of hepatic architecture around the central vein H&EX200.

3.1. After 14 days mix groups(Nigella sativa +Iron) treatment.

Figure (4)Gross section obtained from Liver tissue in male rats 14 days shows presence of hepatic cords ,Also shows presence of Early granuloma due to aggregation of macrophage within the hepatic tissue .Few hemorrhage in the sinusoids mild necrosis of hepatocytes ,Other hepatocytes showed normal and hexagonal shape with prominent and central nuclei, Also there are

binucleated hepatocyte , shows dilatation of sinusoids with proliferation of kupffer cells .Few hepatocytes undergo from fatty change .presence of hepatic cords around the central vein H&EX200.

3.2. After 28 days mix groups (Nigella sativa +Iron) treatment .

Figure (5)Gross section obtained from liver tissue in male rats28days showed marked mitotic division of hepatocytes which, appearance (hexagonal shape with prominent ¢ral nuclei) and few showed as binucleated hepatocytes .Dilation of sinusoids and present of Kupffer cells . with scattered and mild infiltration of macrophages and few congestion in the blood vessels .The hepatocytes showed with normal shape H&EX200 .

4.1. After 14 days Nigella sativa groups treatment.

Figure (6) Gross section obtained from liver tissue in male rat 14 days administration Nanoparticle Nigella sativa treatment . normal radially arrangement of hepatic cords around normal central vein. Binucleated hepatocytes H&EX200 .

4.2. After 28 days Nigella sativa groups treatment.

Figure (7) Gross section obtained from liver tissue in male rat 28 days administration Nanoparticle Nigella sativa treatment .normal radially arrangement of hepatocytes around the central vein. Also there is dilation of sinusoids . proliferation of Kupffer cells H&EX200 .

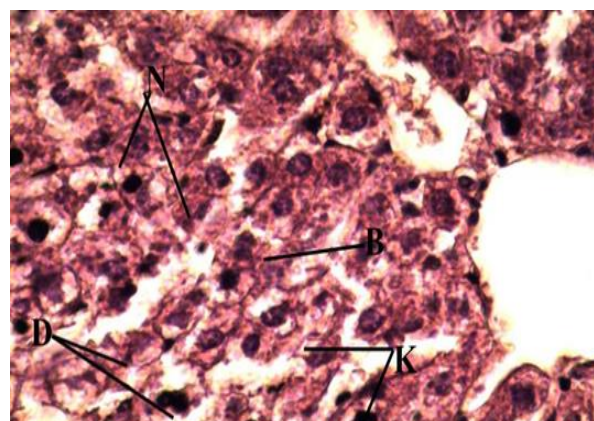
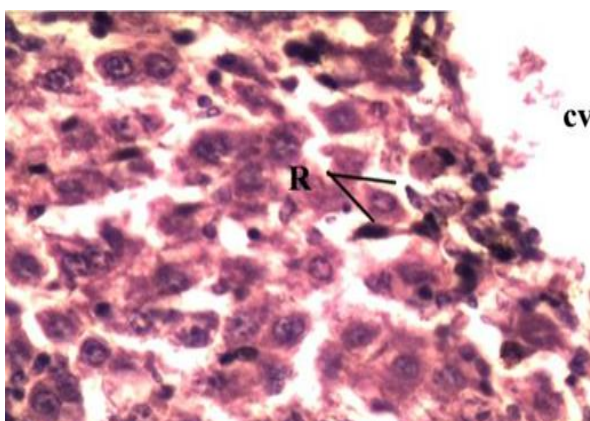


Figure (1) Histopathological change of liver tissue in male rats 14,28 days group (control). (R)There normal hepatic cords(CV)central vein .H&EX200.

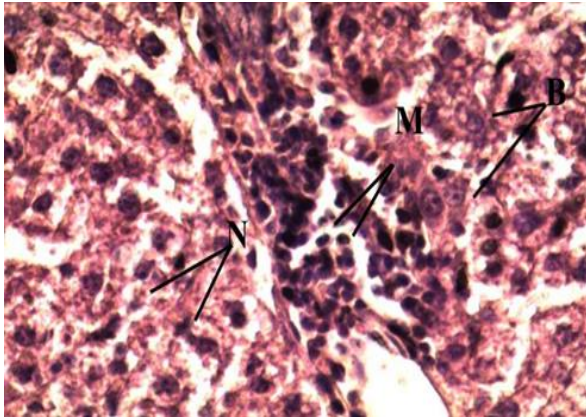


Figure (3)Gross section obtained from liver tissue in male rats 28 days administration Nanoparticle Iron treatment.(M)macrophages cells, (N) necrosis of hepatocytes (B) binucleated cells .H&EX200.

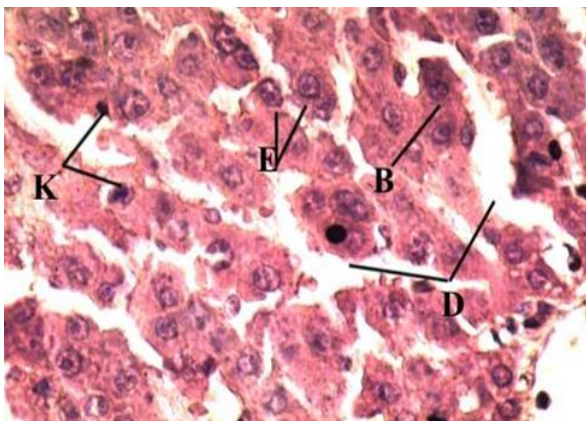


Figure (5)Microscopic section obtained from liver tissue in male rat 28 days administration (Nanoparticle Iron+Nanoparticle Nigella sativa) treatment,(E)central nuclei (B)hepatocytes, (D) sinusoids,(K)kupffer cells.H&EX200.

Figure (2) Histopathological change of liver tissue in male rats 14,28 days Liver tissue in male rat 14 days administration Nanoparticle Iron treatment. (N)There is necrosis of hepatocytes(D)dilution of sinusoid (K) kupffer cells (B) hepatocytes. H&EX200.

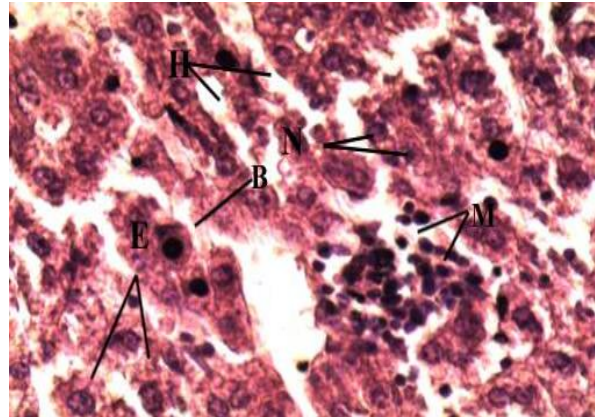


Figure (4)Histopathological change of Liver tissue in male rat 14 administration (Nanoparticle Iron +Nanoparticle Nigella sativa) treatment. (M)macrophages(H)sinusoids,(N)hepatocytes, (E) central nuclei, (B) binucleated hepatocyte. H&EX200.

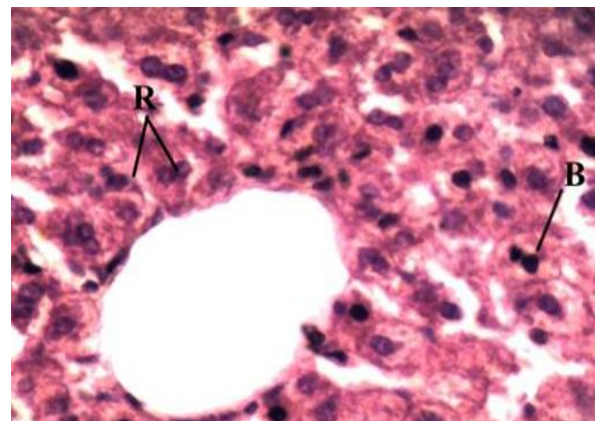


Figure (6) Microscopic section obtained from liver tissue in male rat 14 days administration Nanoparticle Nigella sativa treatment. (B) normal hepatocytes, (R) radially Central vein .H&EX200.

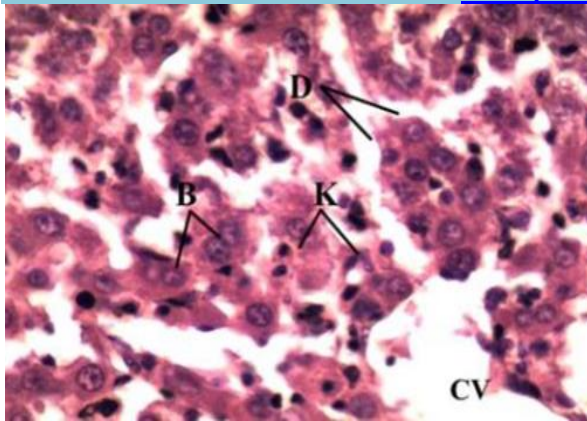


Figure (7) Microscopic section obtained from liver tissue in male rat 28 days administration Nanoparticle *Nigella sativa* treatment, (D) dilution of sinusoids, (B) hepatocytes (CV) central vein, (K) Kupffer cells H&EX200.

Discussion.

This experiment was conducted for the purpose to know the impact of antioxidant nanoparticles of *Nigella sativa* agonist oxidative stress of the Nanoparticles of iron in rats, to studied Histopathological of liver. G1 first group mixed will be orally administered IRONPs (10 mg/kg/day) will be orally administered NSMNP (25 mg/kg/day) rats for 28 days. G2 second group Nm would be orally administered NSMNP (25 mg/kg/day) for 28 days. G3=third group Fe = will be orally administered IRONPs (10 mg/day) rats 28 day. G4= Forth group Control = rats without treatment *Nigella sativa* seed extract provide nutritional support (19) as it is rich in nutritional values protein to fatty acids. (20) and other building blocks for the body such as carbohydrate, proteins, vitamin and minerals (21). It has been shown that the nutritional and medicinal value of *Nigella sativa* effected in improving digestion and providing energy [22]. thus our results revealed slight increase in body weight under normal environment. It is evident that administration *Nigella sativa* extract 28 days appear increase organs weights liver, kidney, spleen, brain in rats (23)(24)(25). (26), Antioxidant Status The effects of dietary black seed support to antioxidant enzymes activities in all the studied tissues and decrease the oxidative stress. The use of black seeds for treatment as a multipurpose "drug" administration oral treatment. TQ is

the activation contain of N S and is responsible its anticancer antioxidant, anti-inflammatory, & antibacterial properties (27). According, the level of dietary iron significantly influences iron absorption. Another important factor in regulating iron absorption relates to the form of iron present in a diet. Heme the two major sources of iron mainly found in meat, fish, and poultry, is more effectively absorbed than non-heme iron due to its association with porphyrin ring (28). (29) In second study, used 1 g *N. sativa* oil twice immunopotentiating and Hepatoprotective effect. The latter pharmacological properties add to be involved in the beneficial (30) effects of N S Antioxidant and hepatic protective effects of black seeds Health food. "Histopathological added control rats Normal: Section studied under H&E stain showed normal parenchymal tissue which is composed of numerous hexagonal to pyramidal lobules. Each lobule consists of central vein from which the hepatic plates radiate outwards the portal areas, portal triads are located at the periphery of the lobule, containing branches of bile duct, portal vein and hepatic artery and occasional mononuclear cells. The sinusoids are lined by both and Kuepfer's cells endothelial cells both of which have inconspicuous flattened nuclei and ill-defined cytoplasmic margins. Cords of hepatocytes and blood containing sinusoids radiate from central vein to the peripheral portal triads.



The central vein are lined by endothelial cells surrounded by ring of collage fibers. The hepatocytes are polygonal in shape with well-defined borders. The nucleus is single, round and has a fine chromatin (31). The results obtained further support from (32) .that histopathological examination of rat's liver treated with RF showed mononuclear infiltration, degenerative changes in hepatocytes and necrosis. The cell is the functional unit of any organ, so cellar abnormality is a good guide to know that such the organ contains such abnormality undergoes a functional disorder. The appearance of hepatic focal area of granulomatous lesion that contain

multinucleated cells (cells of monocyte or macrophage lineage fused together) giant cell, these appearance are regarded as another tension of the functional disorder. In research results ,are confirm these opinions. The histopathological examination of liver at normal dose of NS agrees with mentioned (33).whom showed that chronic inflammation morphological feature are infiltration with mononuclear cells (macrophages, lymphocyte and plasma cell) indicates persistent reaction to injury tissue of inflammatory cells repair in fibrosis attempt to replace damage tissue to improve immune response.

Reference

- Han, X., Li, S., Peng, Z., Al-yuobi, A.S.O., El-Shahawi, M.S. and Leblanc, R.M. (2016). Interactions between Carbon Nano materials and Biomolecules. *J. Oleo Sci.*, 65:1-7
- Raza, M.A., Z, Rauf, A., Sabi, A.N., Rias, S. and Naseem, (2016). Size and Shape Dependent Antibacterial of Silver Nano (4):74
- Cacciotti, I., Chronopoulou, L., Palocci, C., Amalfitano, A., Cantiani Cordaro, M., Lajolo, C., Calla, Boninsegna, A., Lucchetti, D., Gallenzi, P. (2018). Controlled release of 18-B glycyrrhetic acid by nano delivery systems increase cytotoxicity on oral carcinoma cell line. *Nanotechnology*, 29(28): 285101.
- Dwivedi, S.N. (2004). Herbal remedies among triples of siddhi district of Madhya Pradesh, *J Econ. Tax*, 28(3):675-686.
- Nickavar, B.; Mojab, F., Javidnia, K.; Amoli, M.A. (2003). Chemical composition of the fixed and volatile oils of *Nigella sativa* L. from Iran. *Z.Naturforsch C*, 58(9-10):629-631.
- Ali, B.H. and Blunden, G. (2003). Pharmacological and toxicological properties of *Nigella sativa*. *phytother Res* 17: 299-305.
- Al-Ghandi, M.S. (2003). protective effect of *Nigella sativa* seeds against carbon tetrachloride-induced liver damage. *Am J. Chin. Med.*, 31(5): (721-728).
- Kalus U, Pruss A, Bystron J, Jureck M, Smekalova A, Lichius J and kiesewetter H. (2003). Effect of *Nigella sativa* (black seed subjective Feeling in patients with allergen disease. *J. Phytother Res* 17(10): 1209-1214.
- Salem M.L. (2005). Immunomodulatory and therapeutic properties of the *Nigella sativa* L. seed. *Internet Immunopharmacol* 5: 1749 - 1770.
- Morsi, N. (2000). Antimicrobial effect of crude extracts of *Nigella sativa* on multiple antibiotics resistant bacteria. *J. Acta Microbiologica Colonic*. 49(1):63 -74.
- Riaz M, Syed M and Chaudhary F M. Chemistry OF medicinal plants plan genus *Nigella* (Family – Ranunculaceae). *J Hand medicus*. 1996 ;39(2):40-45.
- Musa, D.; Duisiz, N.; Gumushan, H.; Ulakoglu, G., and Muharrem, (2004). Antitumor activity of an ethanol extract of *Nigella sativa* seeds; *J. Biologia Bratislava*. 59:635-670.
- Al - Rowais N A . Herbal medicine in treatment of diabetes mellitus . *Saundi Med. J.*, 2002,
- Zaoui I , Cherrah Y , Mahassini N, Alaoui K, Amar Ouch H, and Hassarssue M. (2002). Acute and chronic toxicity of *Nigella sativa* fixed oil. *J. Phytomedicine* .9(1):3-6
- Szalay B, Tatrai E, Nyiro G, Vezer T, and Dura G . Potential toxic effects effect iron oxide nanoparticles in vivo and vitro experiment. *J. Appl. Toxicol.*, 2017, 32(6):446 - 453. <https://doi.org/10.1002/jat.177>
- Harboron, H.J.; (1984). *Phytochemical methods : A Guide to Mode Techniques of plant Analysis*. Chapman and Hall, London, UK ., pp:1-34.
- Awan, M.A., Akhter, S., Husna, A.U., Ansari, M.S., Rakha, B.A Azam, A.A., Qadeer, S., (2018). Antioxidant activity of *Nigella sativa* Seeds Aqueous Extract and its use for cryopreservation of buffalo spermatozoa. *Andrologia*, 50(6):e13020-e13026.
- Amooaghaie, R., Saeri, M.R. and Azizi, M. (2015) Synthesis, Characterization and Biocompatibility of Silver Nanoparticles Synthesized from *Nigella sativa* Leaf Extract in Comparison with Chemical Silver Nanoparticles. *Ecotoxicology and*



- Environmental Safety, 120, 400-408
<https://doi.org/10.1016/j.ecoenv.2015.06.025>
- 18-Luna, L.G., (1968): Manual of histological staining methods of the mother armed forces institute of pathology. 3rd edition. Mc Graw. Hill too book. Co. London
- 19- Ahmed ,A.,(2004) .Activation of the immune system of Anopheles Gambiae Against Malaria parasite :Acomparisson between bacterial injection and Botanical Extract . International Conference on Biological sciences .3(1):122-141.
- 20- Ramadan, M., and Morsel ,J.(2003).Analysis of glycolipids from black cumin (*Nigella sativa* L.), Conriander (*coriandrum sativum* L) . and niger(*guizotia abyssinica* cass.)oil Seeds .Food chemistry. , 80: 197-204.
- 21- Swami ,S.M.,Tan ,B.K.,(2000).Cytotoxic and immunopotentiating effect of ethanolic extract of *Nigella sativa* L .seeds .;mJ. *Etno-Etnopharmacol.*70:1-7.
- 22- Salem ,M., and Hossein ,M.,(2000). Protective Effect of black seed oil from *Nigella sativa* against murine Cytomegalic virus Infection . ;*J. Immunopharmacology.*22(9):729-740.
- 23-Andaloussi ,A.;Elimadi, A.; Settaf, A. ; cherrah , Y. and Haddad, p (2004).The effect of *Nigella sativa* in the body weight . *Ethno - pharmacology* .94:251-259.
- 24-Kanter,M.; Coskun , O., and Gurel ,A.,(2005).Effect of black Cumin (*Nigella sativa*)on Cadmium induced oxidative in the blood of the rats ;*J.Biol .Trace.Elem.Res.*107(3):277-278.
- 25-AItan,M.; Kanter.M.;Donmez ,.S.;kartal.;M.,and Buyukbas ,S(2007) .Combination therapy of *Nigella sativa* and human parathyroid hormone on bone mass ,biomechanical behavior and structure streptozotocin –induced diabetic rats ,; *Acts His to chemical* (4):304-314.
- 26-Maria Latif 1 , , Mehwish Faheem , Asmatullah , Seyed Hossein Hoseinifar and Hien Van Doan Animals 2021, 11, 48.
<https://doi.org/10.3390/ani11010048>.
- 27-Ijaz, H.; Tulain, U.R.; Qureshi, J.; Danish, Z.; Musayab, S.; Akhtar, M.F.; Saleem, A.; Khan, K.K.; Zaman, M.; Waheed, I.; et al. *Nigella sativa* (Prophetic Medicine): A Review. *Pak. J. Pharm. Sci.* 2017, 30, 229–234.
- 28- Cook JD (1990) Adaptation in iron metabolism. *Am J Clin Nutr* 51: 301–308. PMID: 2407101.
- 29- Hussain M, Tunio AG, Akhtar L, Shaikh GS. Effects of *Nigella sativa* on various parameters in patients of non-alcoholic fatty liver disease. *J Ayub Med Coll Abbottabad* 2017;29:403-7. PUBMED
- 30- Swamy,S.M.,Tan ,B.K.,(2000).Cytotoxic and immunopotentiating effect of of ethanolic extract of *Nigella sativa* L .seeds .;mJ. *Etno-Etnopharmacol.*70:1-7.
- 31-Shaik Hussain Saheb , Desai S D, Kusal K Das, Haseena S. HEPATOPROTECTIVE EFFECT OF NIGELLA SATIVA SEED IN STERPTOZOTOCINE .INDUCED DIABETIC ALBINO RATS: HISTOLOGICAL OBSERVATIONS. *Int J Anat Res* 2016, 4(2):2459-63. ISSN 2321-4287.
- 32-Devendna, S.K., Mond, T. S., Hemant, K.S., Ali, A. and Verma, V. K 2012In vivo Hepatoprotective Potential of *Nigella sativa* Extract against Rifampicin induced sub -chronic Hepatotoxcity and Altered Redox status. *Journal of Biologically Active Product from Nature*, 2(3), pp: 167-177.
- 33-Salem M.L.,(2005).Immunomodulatory and therapeutic properties of the *Nigella sativa* L .seed ,; *Internet Immunopharmacol* 5: 1749 - 1770.