



Using of Rapid test for diagnosis of infectious bronchitis and Study of virus histological changes in Thi-Qar province

Oday jaber Lateef Alabadi , Nafea S. Jasim

Vet. hospital in Thi-Qar, Coll. of Vet. Med. / Univ. of Al-Qadisiya

Corresponding email : aude0552@gmail.com

Abstract

Infectious bronchitis in poultry is one of the economically important diseases in the poultry industry. Study was aimed to diagnose Infectious bronchitis virus (IBV) in broiler chickens using the rapid kit test assay .The current study was completed to diagnose infection in (28) broiler chicken flocks in Thi-Qar province.During the period of October 2020 to May 2021 . Samples were collected – swabs were examination results from a total of (28) fields , (18) fields (64.28%) were positive using the rapid kit test. The results of the microscopic histological examination of the trachea section showed epithelial cell strife and hemorrhage, while in the lung sever exudation of inflammatory cells,in the kidneys were characterized by the presence of degeneration in the renal tubules.

Keywords: Broiler chickens, Histological examination ,IBV , Rapid kit test .

Introduction

Corona viruses(CV) are a type of virus that causes highly infectious respiratory and gastrointestinal diseases in both animals and humans (1). The infectious bronchitis virus (IBV) is a member of the Corona viridae's group III of the genus Corona virus (2). Schalk and Hawn discovered a novel respiratory ailment in young chickens in North Dakota in 1931, marking the disease's initial detection (3). The infectious bronchitis virus (IBV) is a highly contagious disease that creates enormous issues in hens. The most clinically significant kinds of IBV infections in domestic chickens include respiratory, reproductive, digestive, and kidney infections (4). Common symptoms of infectious bronchitis in chicks include struggling to breathe, coughing, sneezing, tracheal rales, and nasal discharge. A chick's moist eyes and swollen sinuses are not uncommon. The chicks appear distressed and are occasionally observed cuddled beneath a heat source.The amount of food consumed and the value of weight gained are also greatly decreased and the disease may go unnoticed unless the flock is closely inspected by handling the birds or listening to them at night while they are usually quiet (5). The virus also affects the urogenital tract, resulting in decreased egg development (6) .The rapid test is an immunochromatographic method for detecting viral antigen in avian secretions like trachea and feces. This test is distinguished by its speed, which can be performed in the field, as well as its low cost when compared to other tests. It is also considered one of the most common screening tests that provides information on the presence of viral antigen. When tracheal swaps containing viruses were employed from infected birds, a colored band emerged in the device line for 10-15 minutes due to positive results, whereas this band faded when negative results (7).

Aims of the study

- 1-diagnosis of infectious bronchitis in Thi-Qar province.
- 2- Study of virus histological changes

Material and Methods

1-Collection of Data

Samples were collected from 28 broiler flocks in different region of Thi-Qar province where infection was expected which suffered from severe respiratory signs with high mortality, signs were gasping, ocular and nasal discharge, grossly there were severe congestion of trachea, with information taken about (age , vaccination programs, food and medication as well as the nature of field management).

2- Diagnosis by Antigen Rapid IBV Antigen Test Kit (BIONOTE, Incorporation, Korea)

Tracheal swabs were collected from (5) chickens per flock by using sterile cotton swab which was inserted inside of the trachea several times. Rapid test kit for the detection of IBV in flock. Several insertions of a tracheal swab into the trachea were followed by the insertion of the swab into a sample collection tube containing assay diluents. The sample was then mixed until it was dissolved in the assay diluents, and the tube was allowed until the big particles fell to the bottom. Then, four drops of supernatant were introduced to the test device's sample hole using a disposable dropper. The purple colour was noticed travelling across the result window in the center of the test gadget when the test began, and the results were read 10 minutes later. Tissue samples (trachea, lung and kidney) were collected from 18 infected fields. these tissues placed in containers and add trizol solution for save and stored in (-20 °C) for histopathological examination, then fixed on 10% formaline solution immediately after removal samples. According to Bancroft (8).

Result

Clinical signs

The result of clinical examination showed that there were respiratory signs (gasping, coughing, tracheal rales, sneezing, wet eyes,

nasal discharge and frothy exudate, may have swollen sinus) . rough feather soiled vent feather was recorded as accompanied by slight diarrhea or soft feces and wet litter, as well as some birds were found dead . Figure (1).




Fig. (1): Respiratory signs (gasping). Fig. (2): Congestion and internal bleeding in the inner wall of the trachea in IB infected chicks.



Gross lesions

Post - mortem examination showed several symptoms in the trachea such as, congestion, exudates, and sometime hemorrhages. Furthermore, it was observed hemorrhages of the trachea and a caseous plug in the bifurcation, caseous pus in the lungs , and nephritis . Figure (2).

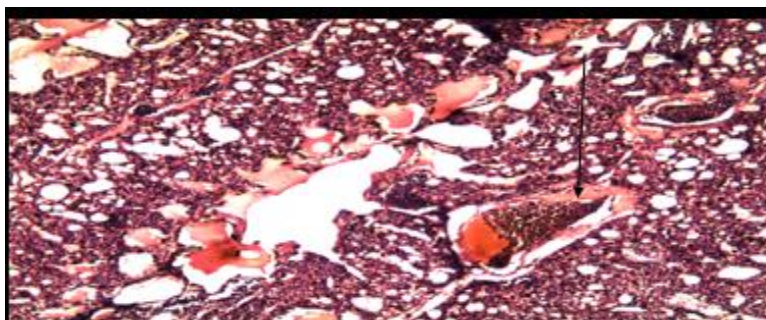


Fig. (3): Marked thickening with infiltration of inflammatory cells in the interstitial tissue. The alveolar sacs showed disappeared and small in size and others showed pulmonary emphysema. Severe hemorrhage and congestion of the blood vessels. The bronchioles showed with narrow lumen and filled with exudate. 10X H&E.

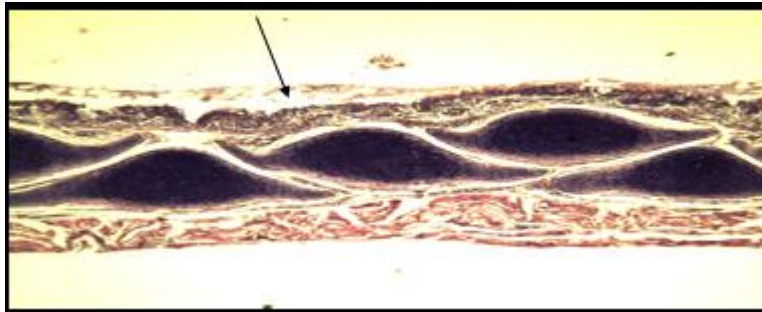


Fig. (4): There is marked thickening of the lamina propria of the tracheal mucosa and inflammatory cell infiltration. Degeneration and desquamation of the ciliated columnar epithelium within the lumen. Degeneration of smooth muscle fibers in muscularis. 4X H&E.

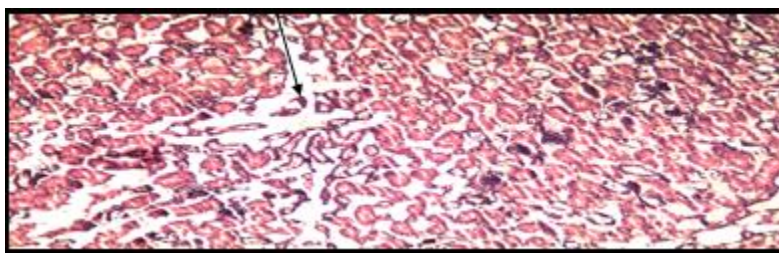


Fig. (5): There is marked atrophy and separation of renal convoluted tubules from the basilar membrane. Degeneration of the epithelial cells which lining the renal tubules. Glomeruli showed small and atrophied . 10X H&E.



Mortalities According to the Age of the Flock 27.77 %, 22.22 %) respectively. The highest percent was at 3th week (50%) while the lowest percent was at 4th week and 5th week were (50%, 5rd week (22.22) . Table (1)

Table (1): Mortality rates in chicks infected with IB at different ages (weeks).

Age (Week)	No. of infected flocks	Mortality
3 rd week	9	50%
4 th week	5	27.77 %
5 th week	4	22.22 %
Total	18	100%

Results of Rapid IBV Antigen Test Kit

The total results of rapid immunochromatographic assay showed that out of 28 flocks were 18(64.28 %) positive for IB, the result showed that the percentages of

rapid test were different among the areas of study when Al-fajr and Al- Rifai revealed the highest percentage (75%) among the other . Table(2).

Table (2): Results of Rapid immune chromatography assay according to the Geographical area:

Area	No. of infected flocks	Rapid test results	%
Nasiriyah	3	2	66.67
Shatrah	3	2	66.67
fajr	4	3	75
Rifai	4	3	75
Suq Al-shuykh	2	1	50
Fuhud	3	2	66.67
alnasr	2	1	50
Bathah	2	1	50
Gharraf	2	1	50
islah	3	2	66.67
Total	28	18	(64.28%)

$X = 36.00, df = 18, p = 0.007$

DISCUSSION

Clinical signs

Clinical signs (IB) (gaspings, coughing, tracheal rales, sneezing, wet eyes, nasal discharge and

frothy exudate, may have swollen sinus) were the most important causes of diseases in broiler chickens in Thi-qar province, Iraq, according to



the results of this study. This result agrees with other studies(9) (10) also agree with (11) in Thi-Qar. (12) Gasping, coughing, sneezing, tracheal rales, and nasal discharge were all recorded by (13) and (14).

Gross lesions

Tracheal congestion, exudates in trachea and sometime there were hemorrhage, cast plug in the bifurcation of the trachea , severe congestion this result according to (15) . Treachiatis, bronchitis, and lung congestion were among the postmortem symptoms, which were followed by caseated plugs at the tracheal bifurcation. Kidney injury in the form of nephritis and urate accumulation in the ureters was observed (13).The infected birds had respiratory symptoms, which were occasionally accompanied by nephritis symptoms like pale kidneys, acute dehydration, and urate deposits in the kidney tubules (16) .

Mortality

In this trial, fatality rates reached up to 35% . This research according to (13), our findings are consistent with those of (17), who showed

clinical symptoms of IBV infection in the birds as well as a 10 to 30% mortality rate. However, this study contradicts (18) findings, which revealed no mortalities in all groups during the experiment. In present study, the three-week mortality rate was the highest, and IB affects chickens of all ages (19). And our findings were also consistent with (20) findings that birds infected when they were young may have maternal immunity .

Results of Rapid IBV Antigen Test Kit

The rapid test is an immunochromatographic method for detecting viral antigen in avian secretions like trachea and feces.The total findings of the quick immunological chromatography assay revealed that 18 (64.28 percent) of the 28 flocks tested positive for IB. This finding agrees with (11) in Thi-Qar, where he found the rate is rapid test (69%) , and (21), while the rate in Diyala (77.5%) was recorded by (22), and the results of the quick immunochromatographic assay revealed that out of 30 flocks, 28 were positive (93.33 percent)positive for IB (7) .

References

- 1- Seger W, Langeroudi AG, Karimi V, Madadgar O, Marandi M V, and Hashemzadeh M . Genotyping of infectious bronchitis viruses from broiler farms in Iraq during 2014-2015. ORIGINAL ARTICLE. 2016; 161:1229–1237.
- 2- Hadipour MM, Azad F, Vosoughi A, Fakhrabadipour M, and Olyaie A. Measurement of antibodies to infectious bronchitis virus in indigenous chicken flocks around maharlou lake in Iran . Int. J. Anim. Vet. Adv. 2011; 3(3): 182-185 .
- 3- Bande F, Arshad SS, Omar A, Bejo MH, Abudbakar MS, and Abba Y. Pathogenesis and Diagnostic Approaches of Avian Infectious Bronchitis . Advances in Virology, ID .2016; 4621659, 11.
- 4- Jackwood MW. Review of infectious bronchitis virus around the world. Avian Dis .2012;56:634–641.
- 5- Kint J, Langereis M A, Maier H J, Britton P, vanKuppeveld FJ, Koumans J, Wiegertjes G F, and Forlenza M. Infectious Bronchitis Coronavirus Limits Interferon Production by Inducing a Host Shutoff That Requires Accessory Protein 5b. J. Virol. 2016; 90, 7519.
- 6- Worthington KJ, Currie RJ, and Jones R C.A reverse transcriptase-polymerase chain reaction survey of infectious bronchitis virus genotypes in Western Europe from 2002 to 2006. Avian Pathology.2008;37, 247257.
- 7- Al-Mahmoudi A H J . Rapid detection of infectious bronchitis virus in broilers in Al-Diwaniya governorate by using Real-Time reverse transcriptase Polymerase Chain Reaction. AL-Qadisiya Journal of Vet. Med. Sci.14 (1),Pp.2015; 22-26.
- 8- Bancroft J, and Steven A. Theory and practice of histological techniques .churchill livingstone , London . 2012;
- 9- Emikpe B O, Ohore O G, Olujonwo M, and Akpavie S O . Prevalence of antibodies to infectious bronchitis virus (IBV) in chickens in southwestern Nigeria .



- African Journal of Microbiology Research.2010; 4(1): 092-095.
- 10- Butcher GD, Shapiro DP, Miles RD . Infectious Bronchitis virus : Classical and variant strains . one of a series of the veterinary medicine large animal clinical sciences department , florida cooperative extension sevice , IFAS.VM127. Extension.<http://edis.ifas.ufl.edu>.2011; Pp 1-4.
 - 11- Al-Fadhili D Y A . Identification of Infectious Bronchitis Virus in Thi-Qar province in Broilers Farms by Using ELISA and rRT-PCR . University of AL-Qadisiya ,College of Veterinary Medicine .2014; P p 112.
 - 12- Mahmoud A M, Shahin A M, and Eid A A M . The Role of Infectious Bronchitis Virus in Respiratory and Renal Problems in Broiler Chickens, Zag Vet J.2019; 47:(1) , p:32-44.
 - 13- Liu S, and Kong X . A new genotype of nephropathogenic infectious bronchitis virus circulating in vaccinated and non-vaccinated flocks in China. Avian Pathol.2004; 33: 321-327.
 - 14- Liu S W, Zhang Q X, Chen J D, Han Z X, Liu X, Feng L, Shao Y H, Rong J G, Kong X G, and Tong G Z . Genetic diversity of avian infectious bronchitis coronavirus strains isolated in China between 1995 and 2004. Arch. Virol.2006; 151: 1133-1148.
 - 15- Abdel-Moneim A S, El-Kady M F, Ladman B S, and Gelb J J . S1 gene sequence analysis of a nephropathogenic strain of avian infectious bronchitis virus in Egypt . Virology Journal.2006; 3: 78 .
 - 16- Yousefi Y, Bassami M R, Kalidari G A, and Seno M M G. Sequence characterization of full-length S1 gene of infectious bronchitis viruses isolated from poultry farms in Khorasan Razavi, Iran. Turk J Vet Anim Sci .2019; 43: 235-243.
 - 17- Sun C, Han Z, Ma H, Zhang Q, Yan B, Shao Y, Xu J, Kong X, and Liu S . Phylogenetic analysis of infectious bronchitis coronaviruses newly isolated in China, and pathogenicity and evaluation of protection induced by Massachusetts serotype H120 vaccine against QX-like strains. Avian Pathology .2011;40(1), 4354.
 - 18- Sediek M E, and Awad A M . Pathogenicity Assessment of Seven Variants of Infectious Bronchitis Virus Isolated from Commercial Broiler Chickens during 2013 in Egypt. J.World's Poult. Res. 2013;4(3): 64-74.
 - 19- Britton P, and Cavanagh D . Avian coronavirus diseases and infectious bronchitis vaccine development. In: Coronaviruses: Molecular and Cellular Biology. Thiel V., ed. Caister Academic Press, Norfolk, UK.2007; 161–181.
 - 20- Jackwood MW, and Lee D H . Different evolutionary trajectories of vaccine-controlled and non-controlled avian infectious bronchitis viruses in commercial poultry. PLoS ONE.2017; 12, e0176709.
 - 21- AL-Zamili W N . Detection of Avian infectious bronchitis virus (IBV) in chicken using serological and molecular methods. MSC.Thesis-Collage of Veterinary Medicine-Bagdad University-Iraq.2013;
 - 22- Alazawy A K S, Abdulhussain S R, Nasser A T, Albaldawy A A A, Bande F, and Jameel G H . Serological Survey and Molecular Detection of Infectious Bronchitis Virus in Broiler Chickens in Diyala Province, Iraq . Int. J. Poult. Sci.2017; 16 (3): 88-92 .