



## Pathological Findings of Respiratory Diseases in one Hump Camel (*Camelus dromedaries*) in Wasit governate

Zainab Ismail Ibrahim

Department of Pathology and Poultry Diseases/University of Baghdad

Corresponding author: [zainabaalrubaei@covm.uobaghdad.edu.iq](mailto:zainabaalrubaei@covm.uobaghdad.edu.iq)

### Abstract

**Background:** Respiratory diseases represent one of the infectious diseases which caused serious effects in animals and important loss economic products as in case of camels.

**Methodology:** The current study included twenty clinical respiratory disorders in one Hump Camel (*Camelus dromedaries*) from eastern-south area in Iraq were it's the living environment of these animals.

**Results:** Respiratory symptoms varying from coughing, nasal discharge fatigue and raised their temperature, weakness, loss of appetite and lost weight. Post-mortem examination of camels carcasses in abattoir investigate stages of pneumonia and pleuropneumonia characterized as heavy-weight of their lungs were edematous, congested with rounded and flabby edges, pale-pink color to gray consolidation with emphysematous areas and petechial hemorrhage sometimes. On microscope acute pulmonary edema and congestion were predominant, bronchitis and bronchiolitis, emphysema and collapse with pleurisy.

**Conclusion:** predominant respiratory infection in camels may due to pathogenic agents from bacteria or viruses may even two agents in mixed infection together causes' serious respiratory distress.

**Keywords:** camel, pathological changes, respiratory infections.

### Introduction

The camel's economy is of considerable importance particularly in arid countries. Camel milk and meat are considered important sources of proteins for a wide population (1). In general camels are resistant to certain infections, whereas they are highly susceptible to a wide range of infectious diseases (2,3). Camel susceptibility to infection with *Brucella abortus* and *Brucella melitensis* has been widely documented (4,5). Evidence of camel Paratuberculosis infection was also voluminous (5,6) and camel infestation with different parasites and protozoa was widely recorded (6,7). The susceptibility of camels to infections with different viral diseases has also been studied (5). Various camel infectious diseases are considered prime zoonosis diseases that threaten public health, such as middle east respiratory syndrome coronavirus (MERS-

CoV) (8) and tuberculosis (9). Pneumonia is one of common respiratory disease of domestic animals including camels. It's an inflammation of the lung caused by direct infection (inhalation) with viruses, bacteria and fungi (10). These viruses were infected respiratory infections in camels are parainfluenza 3, influenza virus A and B, adenovirus, respiratory syncytial virus (RSV) and infectious bovine rhinotracheitis (IBR) (11). The study aimed to investigate the pathological changes grossly and microscopically for camels' respiratory diseases.

**Keywords:** respiratory system infections, camel, pathological changes.

### Materials and Methods

#### Materials

**Animals:** twenty camels from both sexes male and female aged between 2-4 months slaughtered in abattoirs of Wasit governorate in eastern-south region, Iraq. The clinical investigation of the animals expressed signs of respiratory distress varied from fever, nasal discharge predominantly mucus greenish in

color, coughing, fatigue and weakness, loss of their appetite and emaciation.

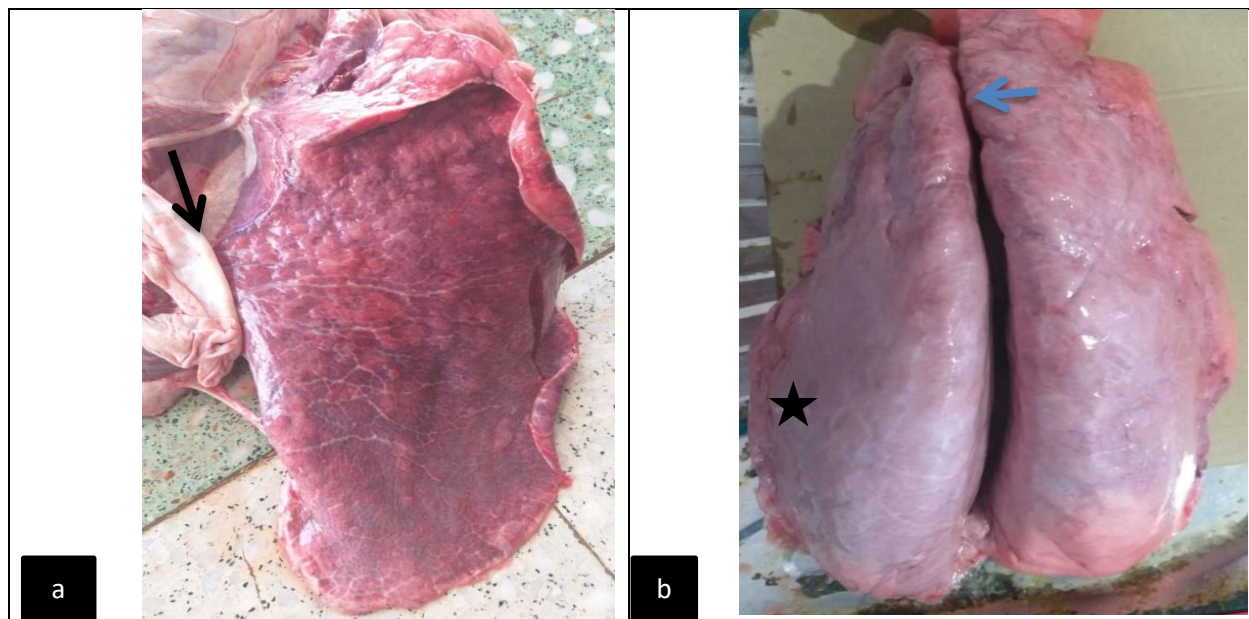
**Lung specimens:** postmortem examination done for carcasses and autopsies from affected lung preserved in 10% formalin for routine histopathological preparation and staining by hematoxylin and eosin (12).

## Results

**Clinical signs:** the physical examination noted moist crackles heard in auscultation with shallow respiration, coughing, fever, nasal discharge, weakness, loss of appetite and their weights.

**Gross lesions:** the predominant pulmonary lesions characterized by congestion and edema, petechial hemorrhage on the surfaces of lungs and heavy weight, pale-pink colored in raised

areas of emphysema, rounded and flabby edges also noted (Figure-1a). There were lobes of gray consolidation appeared dark red to gray in color, sometimes the lung appeared enlarged and swollen covered with whitish-fibrinous meshwork (Figure-2b), mild petechial and ecchymosis hemorrhage seen. The trachea and bronchi showed congestion, and presence of edematous fluid.



**Figure-1:** Gross appearance of affected lung showed (a) pulmonary consolidation and multiple raised-pink foci of emphysema (black arrow) with flabby edges. (b) Enlarged Lung and the dorsal surface covered with whitish-layer of fibrin (star) also apical petechial hemorrhage seen (blue arrow).

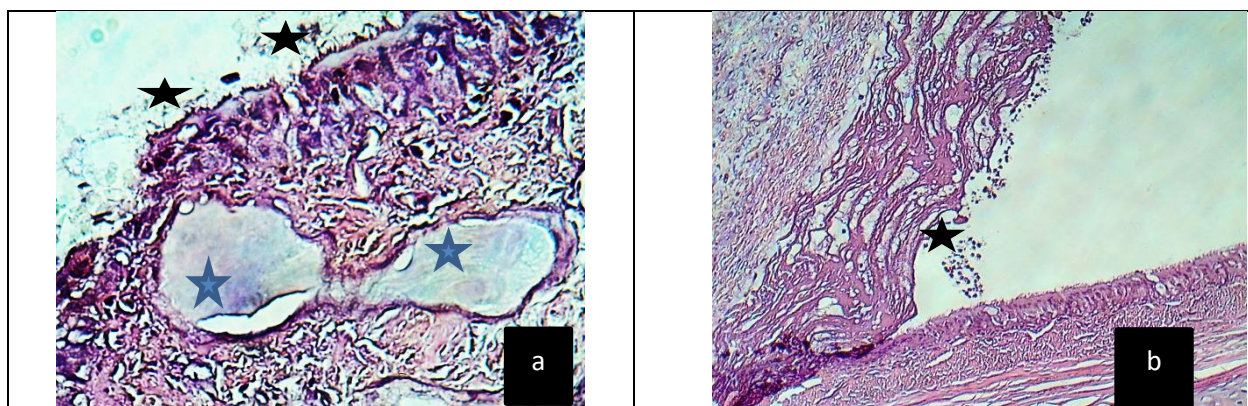
**Microscopic findings:** The lesions of respiratory system showed; the mucosal epithelium of trachea lost their cilia, erosion and necrosis of pseudostratified columnar epithelium (Figure-2a) and thickening of

submucosa due to inflammatory cells infiltration and swelling of mucus glands which caused atrophy of muscular coat, thick layer of fibrin adhered to surface mucosa (Figure-2b). The bronchi and bronchioles dilated with

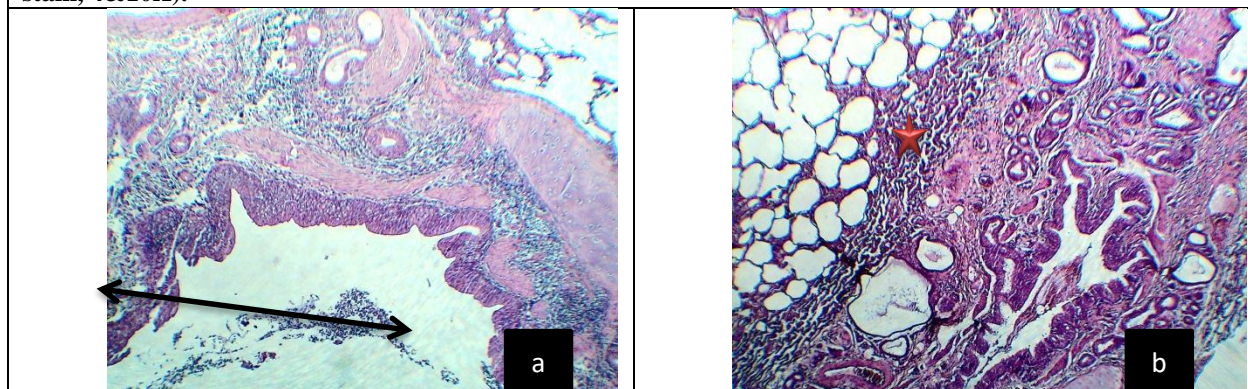


epithelial desquamation, necrosis and presence of inflammatory exudate in their lumens, sometimes hyperplasia and hypertrophy of small bronchioles (Figure-3a). The pulmonary tissues predominantly with interstitial bronchopneumonia; described as bronchitis and bronchiolitis with desquamation and degeneration of epithelium of mucosa and hyperplasia of goblet cells also hypertrophy of muscular layer (Figure-3b), mild pleurisy, emphysema and alveolar collapsed seen. The

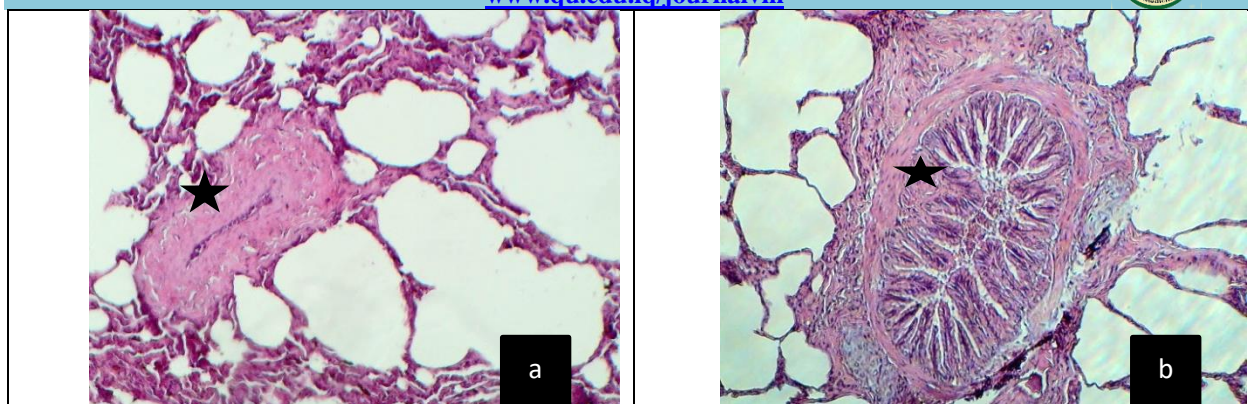
tissue sections showed hypertrophy of large and small pulmonary arteries completely occluded and contained exudate inflammatory cells and RBCs also (Figure-4). Other lung tissues appeared with fibrinosuppurative bronchopneumonia characterized by massive infiltration of polymorphonuclear cells which filled the alveolar lumen (Figure-5) caused severe damage of their tissues extended to pleura to complete adherent



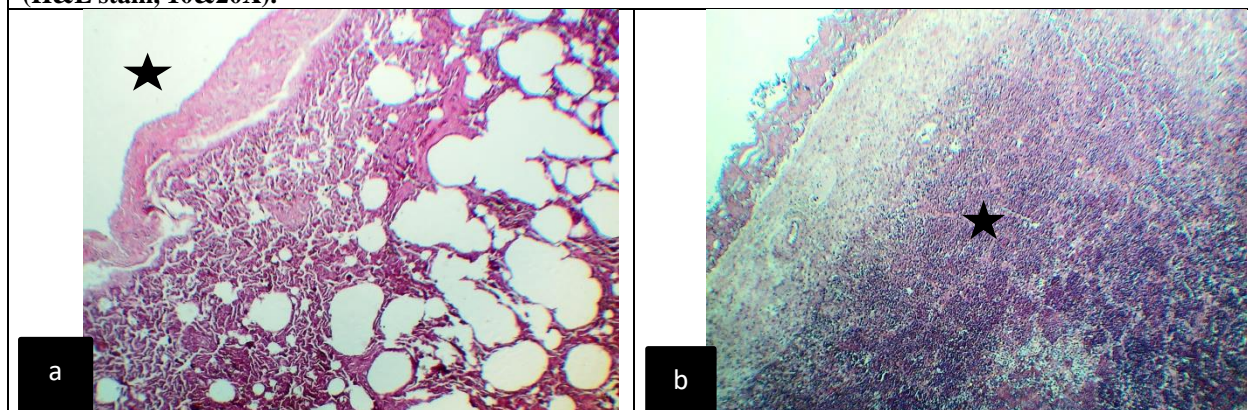
**Figure-2:** Histopathological section in trachea; showed (a) Loss of cilia and erosion of mucosal pseudostratified columnar epithelium (star), and in submucosa dilated mucus glands filled with mucopolysaccharide (bluish) (blue star). (b) thick layer of fibrinous exudate attached to mucosa (star). (H&E stain, 4&10X).



**Figure-3:** Histopathological section in bronchus; (a) Bronchiectasis and peribronchial infiltration and inflammatory cells in lumen (↔) (b) proliferative bronchiolitis and hyperplasia of mucus gland (red star). (H&E stain, 20X).



**Figure-4: Histopathological section in bronchioles; showed (a) hypertrophy of pulmonary artery (star) complete occlusion and emphysema. (b) Bronchiole occluded with papillary hyperplasia (star) of mucosa. (H&E stain, 10&20X).**



**Figure-5: Histopathological section in lung; showed (a) thick pleura (star) atelectasis and emphysema.(b) fibrinosuppurative pleuropneumonia the exudate filled whole alveoli like mosaic appearance (star). (H&E stain, 20&10X).**

## Discussion

Pneumonia is a complex interaction between environment, microorganisms and host immune response (13, 14). Various responses of the living host to inflammation, infection or trauma are collectively referred to as the acute phase response (15). The camel's susceptible to variant infectious diseases caused by certain infectious agents (16) that may agree with current clinical data registered from twenty animals from one Hump Camel in Wasite south of Iraq includes various pathological changes and inflammatory reactions in respiratory organs which caused pneumonia due to viruses, bacteria exclusively suppurative bronchopneumonia in camel as noted in examined lungs.(17) Observed the

histopathological changes caused by viral infections and submitted by the Fluorescence antibody technique (FAT) was accurate sensitive diagnostic method for detection of virus than ELISA. The present study revealed healthy camels slaughtered in abattoirs have been recorded to have one or more lung lesions during postmortem inspection that agreed with (18, 19) who confirmed from postmortem examination of slaughtered camels lungs disease. Acute and chronic suppurative, fibrinous, and interstitial bronchopneumonia was the prevalent lesions in dromedary lungs (20, 21). The study of (22) described the histopathological lesions of camel lungs stained with Hematoxylin and Eosin lesions of



pneumonia in different stages and inflammatory exudates like fibrinous, suppurative or fibrinosuppurative and interstitial pneumonia compatible with current investigation of pneumonia in camels also lesions of pleurisy. These results may occurred from mixed infectious agents viruses with bacteria, the latter consider opportunistic infection may causes severe exudative inflammation consist from fibrin meshwork and purulent exudate responsible for marked destruction of alveolar walls and extended to cause permanent adhesion after healing with fibrous connective tissue to cause respiratory distress due to organization may lead to death.

### Conclusion

### References

- 1-Saeed Y. Al Ramadan, Kazem T. Al-Mohammed Salem, Ibrahim H. Alshubaiith, Ahmed M. Al-Ali, Salah Abohelaika, Mohammed S. Moqbel, Ahmed M. Alluwaimi.(2021). Selected Aspects of Camel Immune System and Immune Responses. **Open Journal of Veterinary Medicine**, 2021, 11, 177-211 <https://www.scirp.org/journal/ojvm> ISSN Online: 2165-3364 ISSN Print: 2165-3356.
- 2-Mohammadpour, R., Champour, M., Tuteja, F. and Mostafavi, E. (2020) Zoonotic Implications of Camel Diseases in Iran. *Veterinary Medicine and Science*, 6, 359-381. <https://doi.org/10.1002/vms3.239>.
- 3-Plasil, M., Mohandesan, E., Fitak, R.R., Musilova, P., Kubickova, S., Burger, P.A. and Horin, P. (2016) The Major Histocompatibility Complex in Old World Camelids and Low Polymorphism of Its Class II Genes. *BMC Genomics*, 17, 167. <https://doi.org/10.1186/s12864-016-2500-1>.
- 4-Abbas, B. and Agab, H. (2002) A Review of Camel Brucellosis. *Preventive Veterinary Medicine*, 55, 47-56. [https://doi.org/10.1016/S0167-5877\(02\)00055-7](https://doi.org/10.1016/S0167-5877(02)00055-7).
- 5-Abbas, B. and Omer, O. (2005) Review of Infectious Diseases of the Camel. *Veterinary Bulletin*, 75, 1-16. <https://doi.org/10.4236/ojvm.2015.57021>.
- 6-Alluwaimi, A.M. (2015) Paratuberculosis Infection in Camel (*Camelus dromedarius*): Current and Prospective Overview. *Open Journal of Veterinary Medicine*, 5,153.
- 7-Parsani, H., Singh, V. and Momin, R. (2008) Common Parasitic Diseases of Camel. *Vet World*, 1, 317-318.
- 8-Dudas, G., Carvalho, L.M., Rambaut, A. and Bedford, T. (2018) Mers-Cov Spillover at the Camel-Human Interface. *Elife*, 7, e31257. <https://doi.org/10.7554/eLife.37324>
- 9-Zhu, S., Zimmerman, D. and Deem, S.L. (2019) A Review of Zoonotic Pathogens of Dromedary Camels. *Ecohealth*, 16, 356-377.
- 10-Ulrich, W.; Oskar, R. K. Infectious diseases in camelids. Black well science berlin, vienna.2002
- 11-Dioli M. and Stimmelmery R. Important camel diseases In: the one humped camel in eastern Africa. pp 199-203. Edited by Schwartz H.J.. and Dioli M., Verlag Josef Margraf 1992. Scientific Books P.O. Box 105D 6992-Wekersheim-F-R-Germany.
- 12-Luna L G (1968) Manual of histologic staining methods of the armed forces institute of pathology. 3rd edn.McGrawHill, New York, NY.
- 13-Bekele T, Kasali OB, Woldeab T (1992). Causes of lamb morbidity and mortality in the Ethiopian Highland. *Veterinary Research Communications*, 16 (6): 415-424.
- 14-Ertan ORUC (2006). The pathologic and bacteriologic comparison of pneumonia in lambs. *Turkish Journal of Veterinary and Animal Sciences* 30(6):593-599.
- 15-Jain S, Gautam V, Naseem S (2011). Acute-phase proteins: As diagnostic tool. *Journal of Pharmacy and Bioallied Sciences*, 3 (1): 118-127.
- 16-Kebede, F. and Gelaye, E. (2010) Studies on Major Respiratory Diseases of Camel (*Camelus dromedarius* ) in Northeastern Ethiopia. *African Journal of Microbiology Research* , 4, 1560-1564.
- 17-Muna E. A, Ali Y H, Zakia A. M, Abeer A. M1, Halima M.O and Manal, H Salih. (2015). Histopathology of Multiple viral infections in lung of



- camel (*Camelus Dromedaries*) in Sudan. IOSR Journal of Agriculture and Veterinary Science (IOSR-JAVS) e-ISSN: 2319-2380, p-ISSN: 2319-2372. Volume 8, Issue 11 Ver. I (Nov. 2015), PP 89-94. [www.iosrjournals.org](http://www.iosrjournals.org). DOI: 10.9790/2380-081118994
- 18-Bekele ST (2008). Gross and microscopic pulmonary lesions of camels from Eastern Ethiopia. Tropical Animal Health and Production, 40 (1): 25-28.
- 19-Jenberie S, Awol N, Ayelet G, Gelaye E, Negussie H, Abie G (2012). Gross and histopathological studies on pulmonary lesions of camel (*Camelus dromedarius*) slaughtered at Addis Ababa abattoir, Ethiopia. Tropical Animal Health and Production, 44(4): 849-854.
- 20-Awol N, Ayelet G, Jenberie S, Gelaye E, Sisay T, Nigussie, H (2011). Bacteriological studies on pulmonary lesions of camel (*Camelus dromedarius*) slaughtered at Addis Ababa abattoir, Ethiopia. African Journal of Microbiology Research Vol, 5(5), 522-527.
- 21-Al-Tarazi YH (2001). The bacteriological and pathological study of pneumonia in the one-humped camel (*Camelus dromedarius*) in Jordan. Revue D Élevage Et De Médecine Vétérinaire Des Pays Tropicaux, 54(2): 93-97.
- 22-Bakhet G. K., Abd ElGhaffar S. K., Ahmed M. A. (2021). Acute-phase proteins: As a diagnostic tool in pneumonic dromedary Camel. SVU- International Journal of Veterinary Sciences, 4 (2): 51-59,. Print ISSN: 2535-1826 Online ISSN: 2535-1877. DOI: 10.21608/svu.2021.61186.1107.